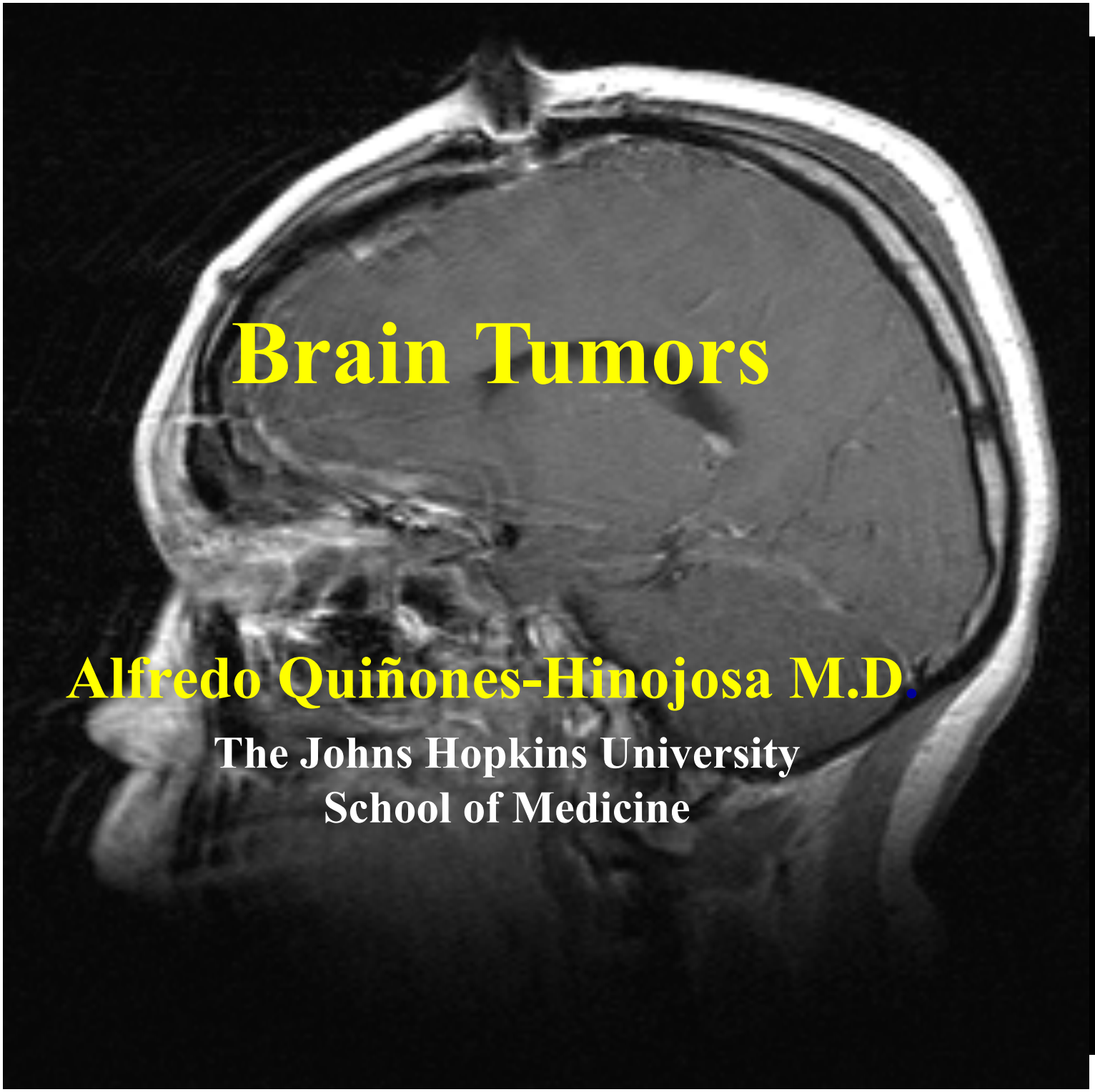

Brain Tumors

Alfredo Quiñones-Hinojosa M.D.

The Johns Hopkins University
School of Medicine

OBJECTIVES

- HISTORY
- TYPES OF TUMORS
- TREATMENT
- POSSIBLE ETIOLOGY
- FUTURE/RESEARCH

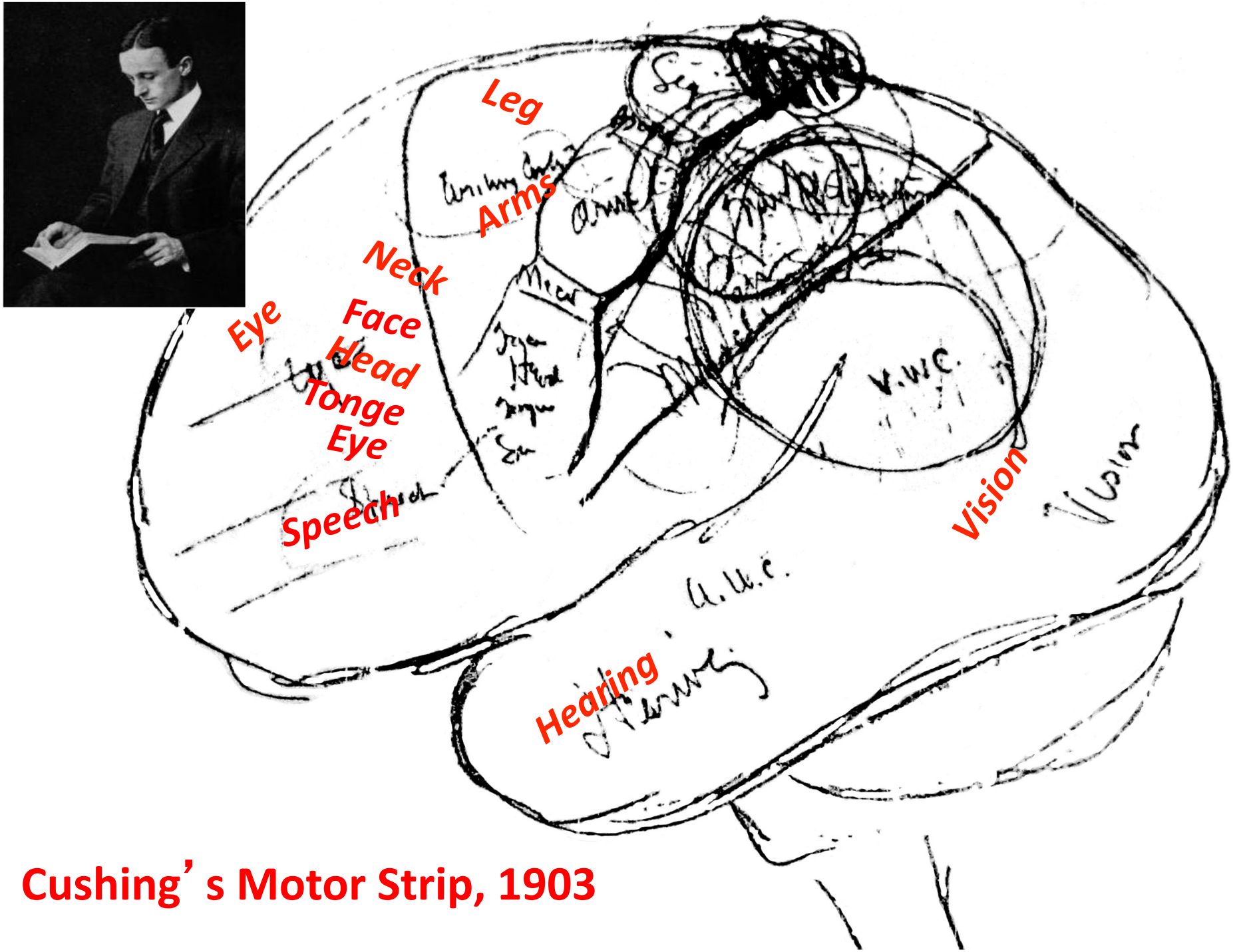

Cushing's Motor Strip, 1903

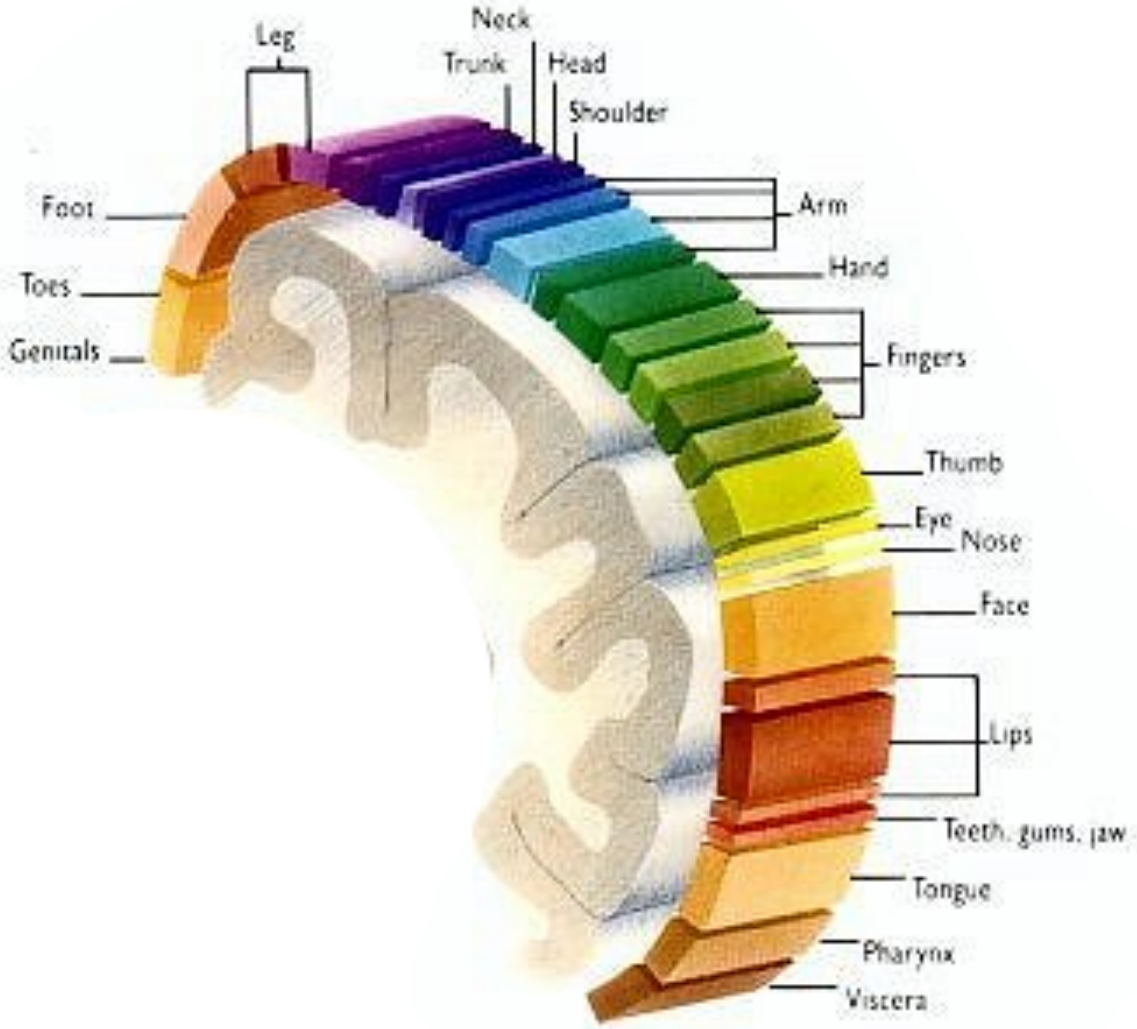
Leg
Neck
Trunk
Head
Shoulder
Foot
Arm
Toes
Hand
Genitals
Fingers
Thumb
Eye
Nose
Face
Lips
Teeth, gums, jaw
Tongue
Pharynx
Viscera

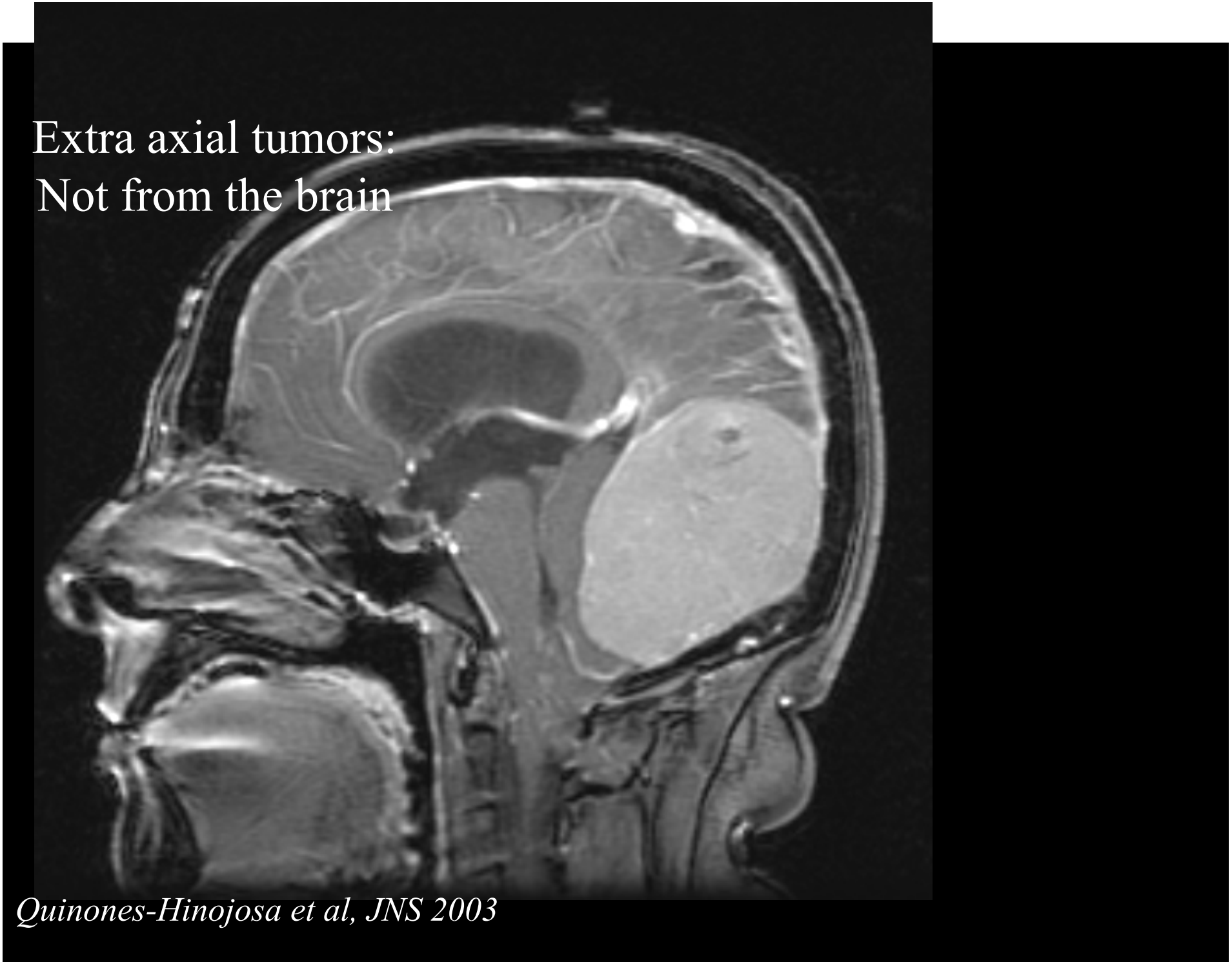

Quinones-Hinojosa et al, JNS 2003

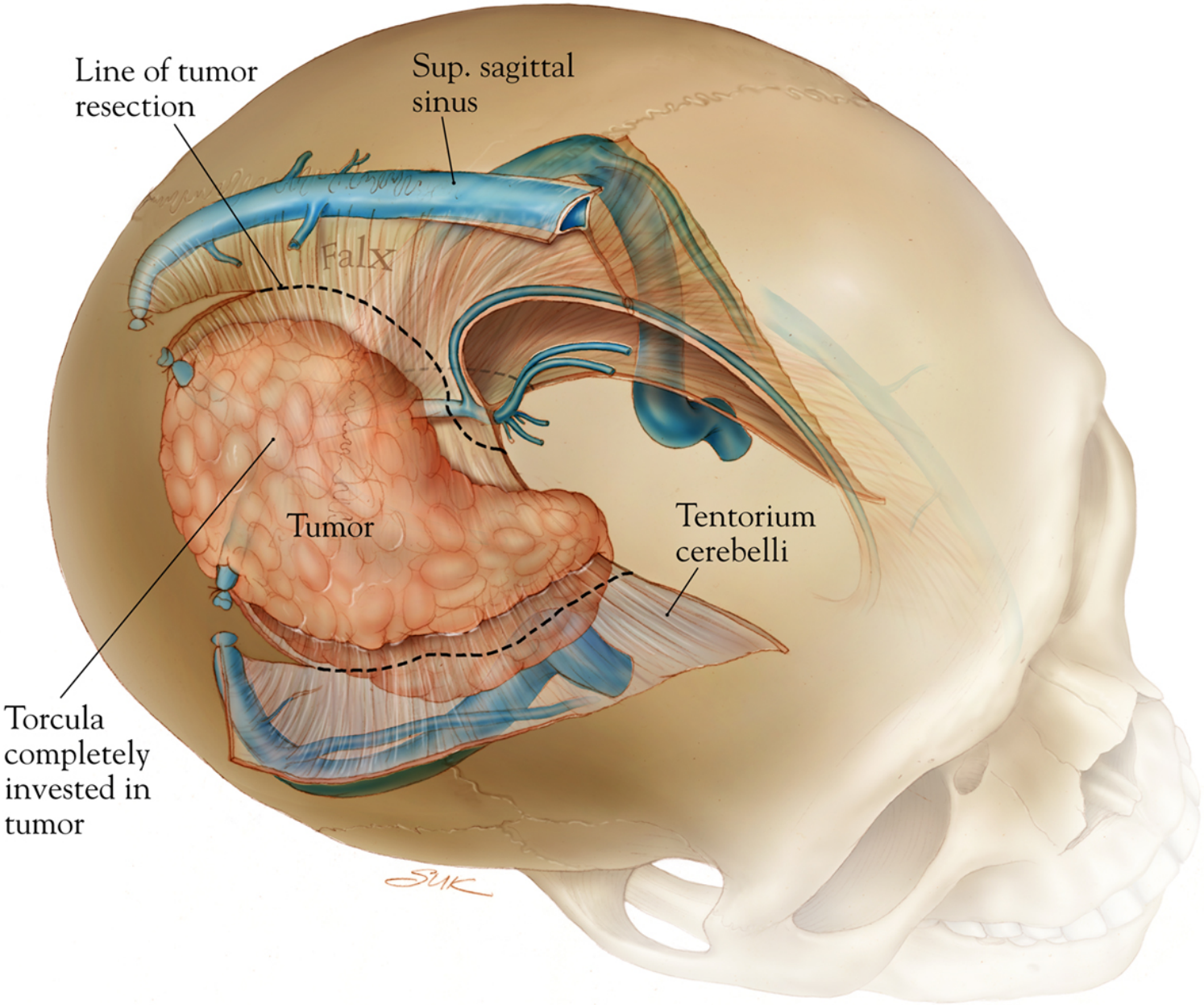

Quinones-Hinojosa et al, JNS 2003

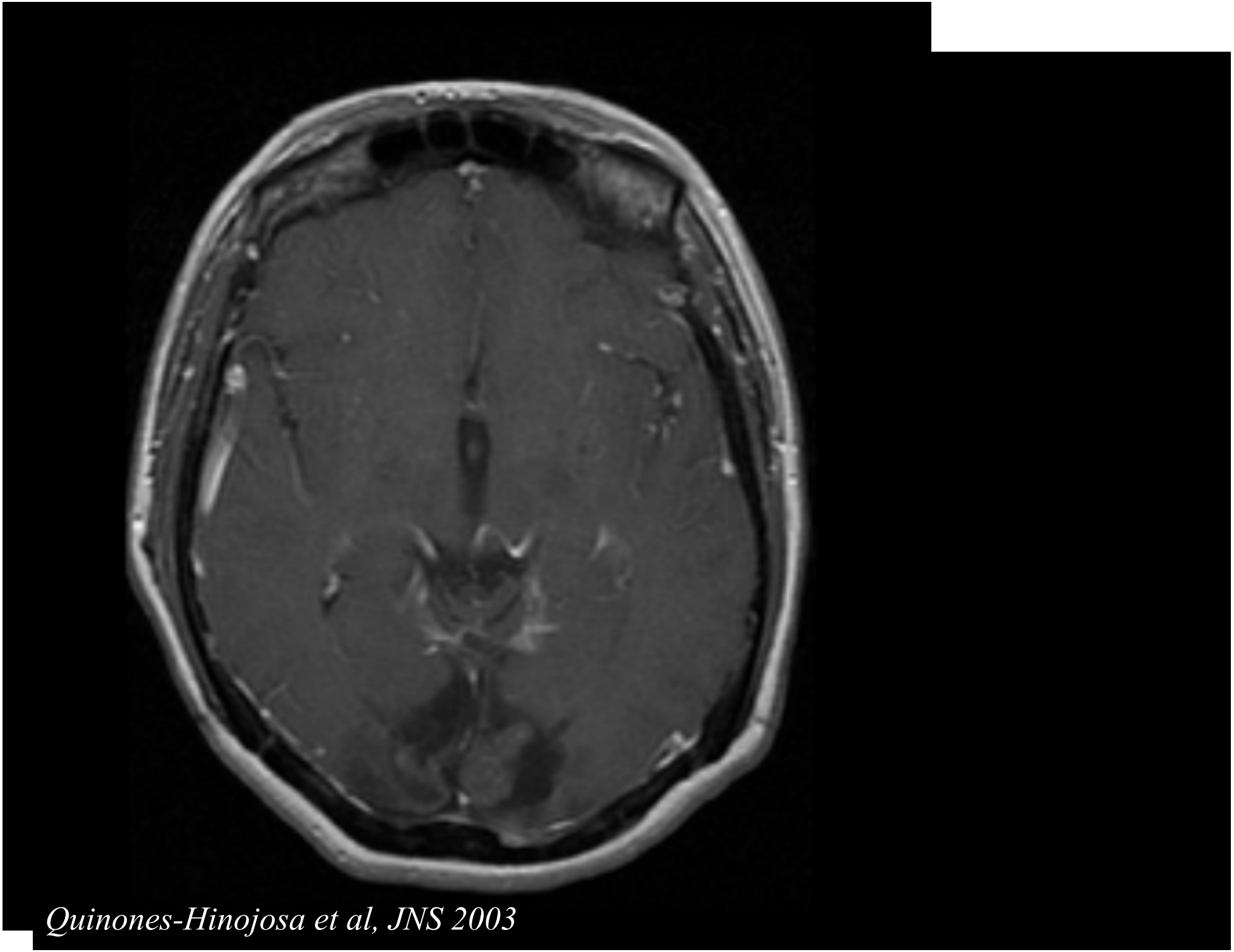

Quinones-Hinojosa et al, JNS 2003

Case Presentation

- 38yo previously healthy female
- presented to the ED with severe headaches
- experienced diminished smell and taste over the course of one year.
- flat affect and decreased smell.

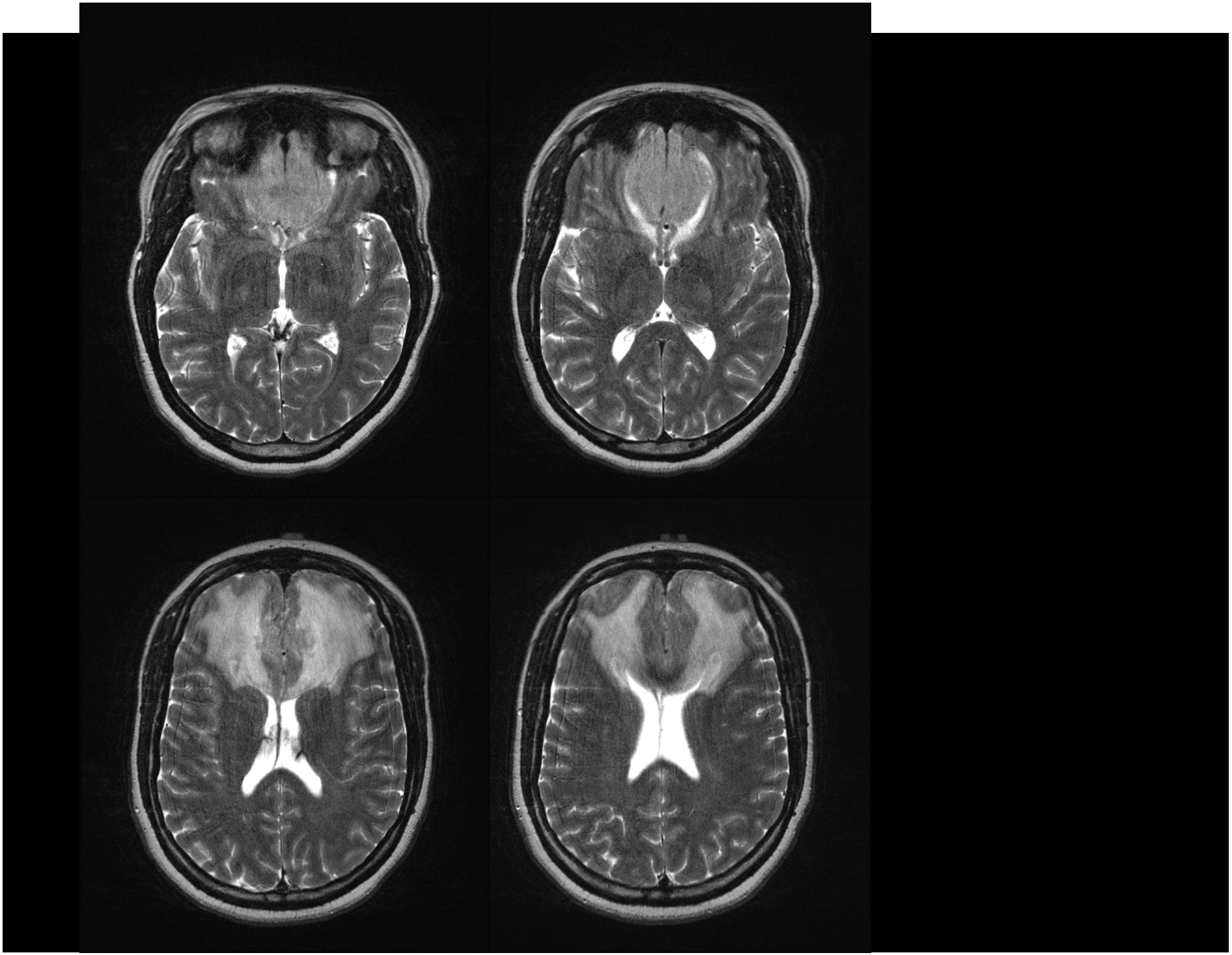

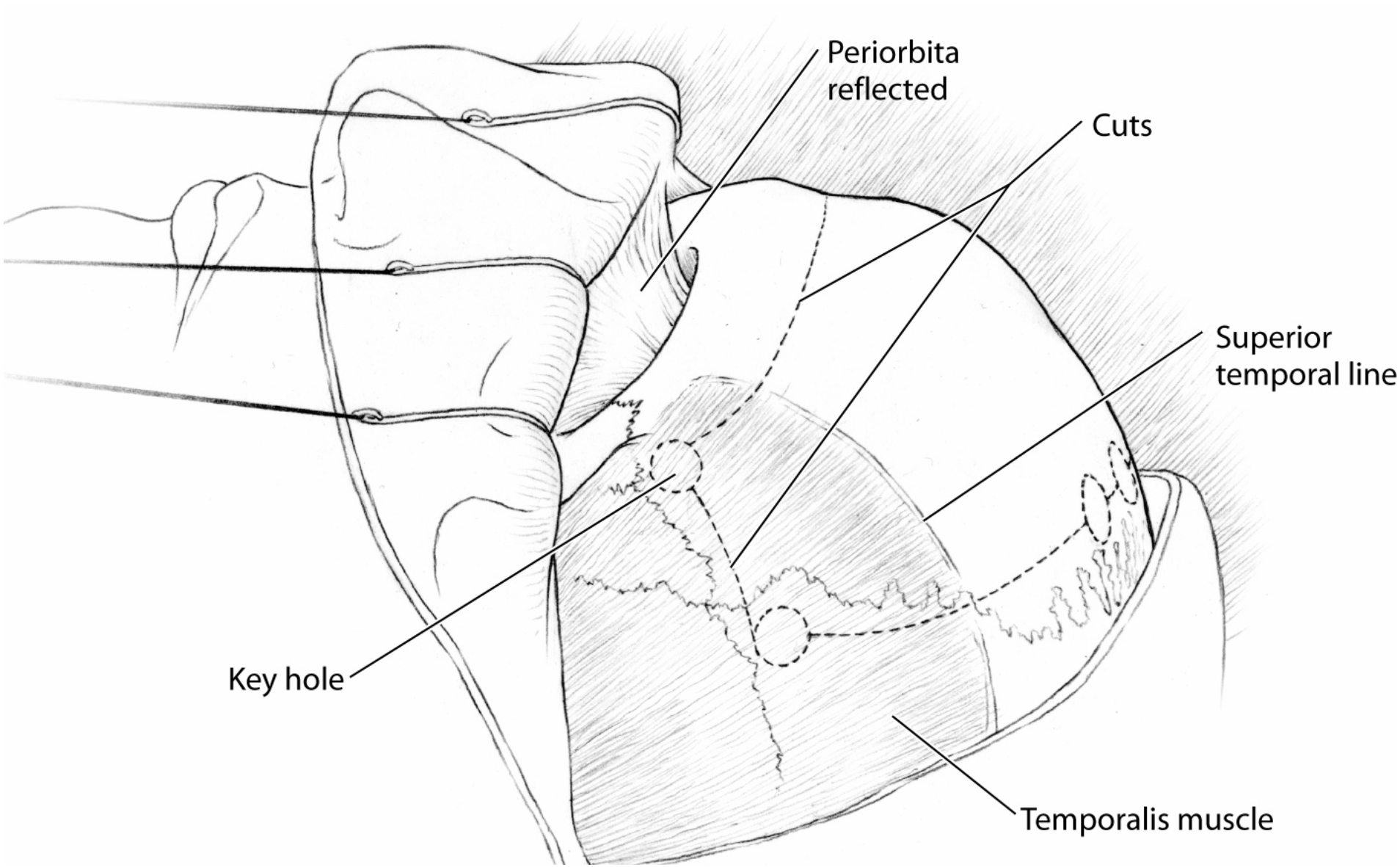
Periorbita
reflected
Cuts
Superior
temporal line
Key hole
Temporalis muscle

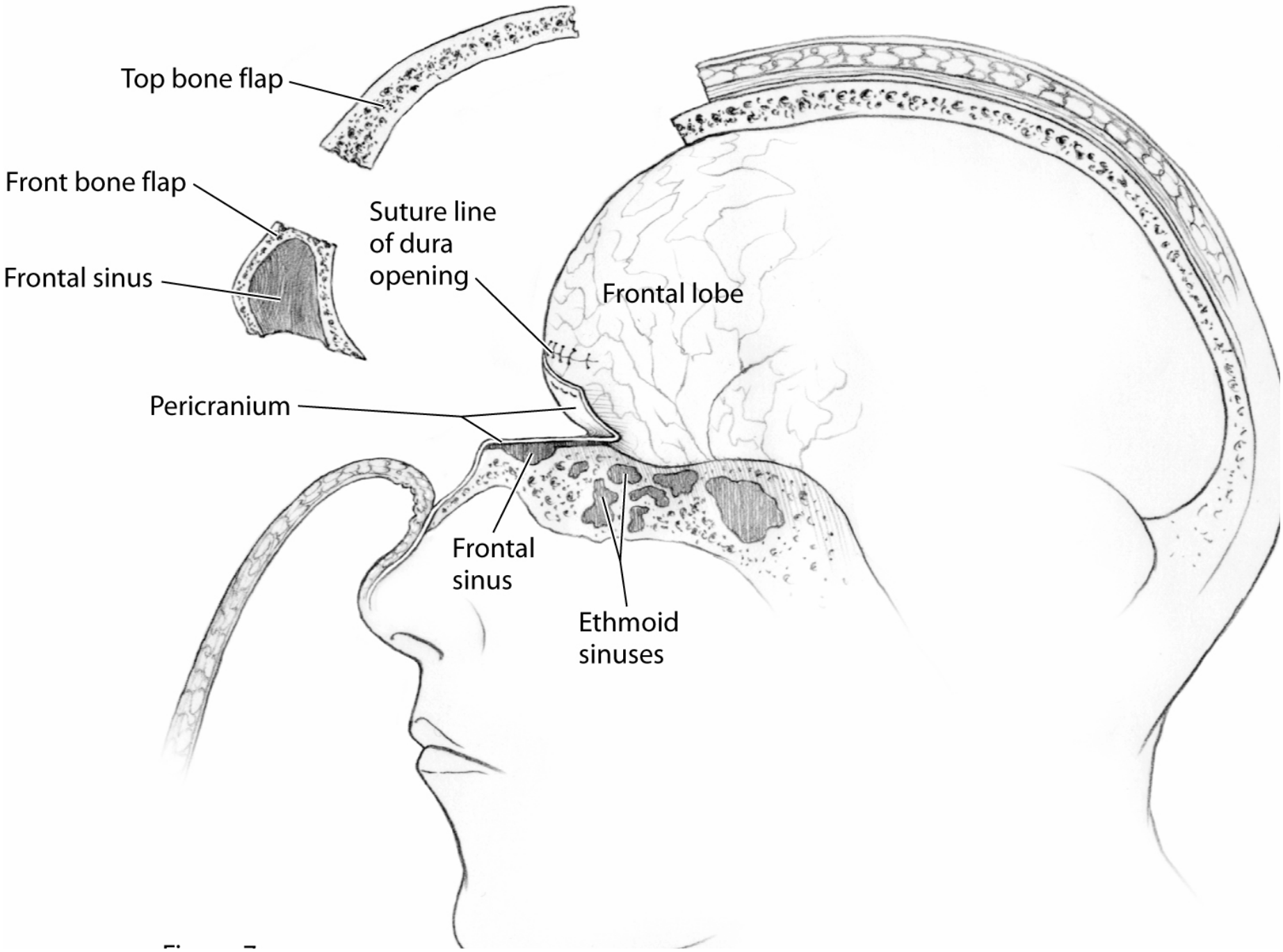
Top bone flap
Front bone flap
Frontal sinus
Suture line
of dura
opening
Frontal lobe
Pericranium
Frontal
sinus
Ethmoid
sinuses

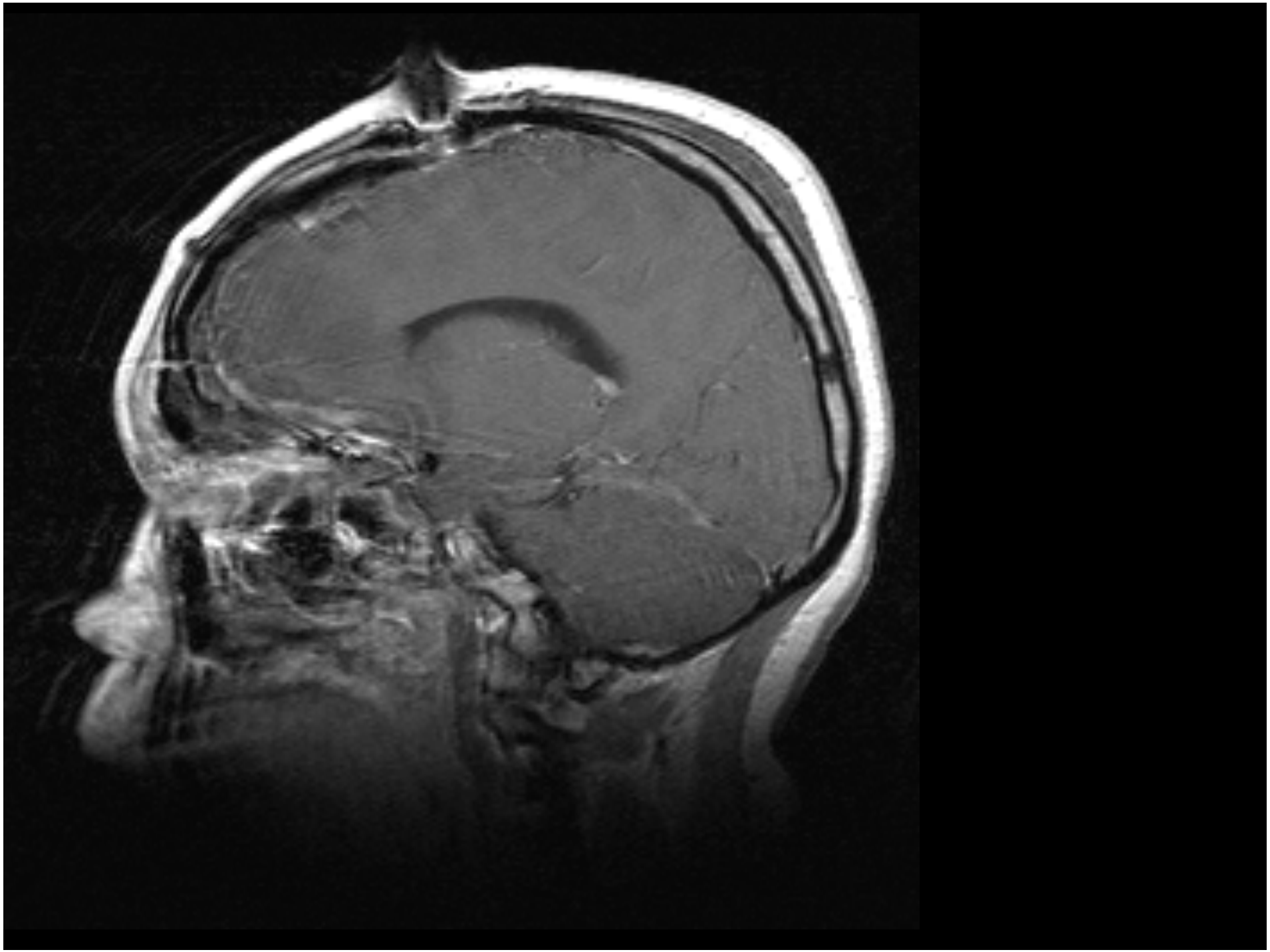

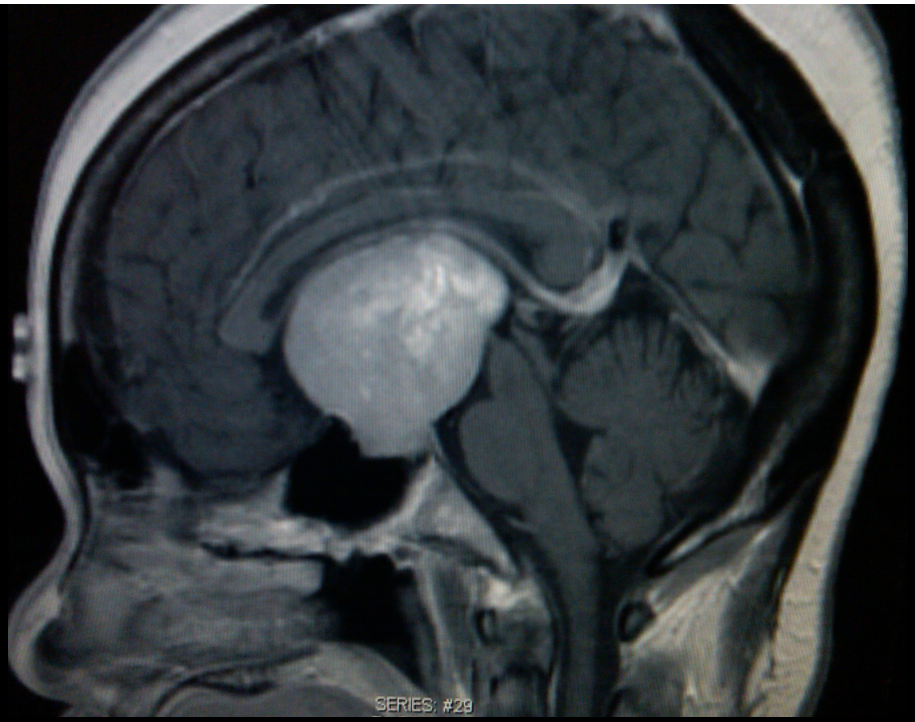
SERIES: #29

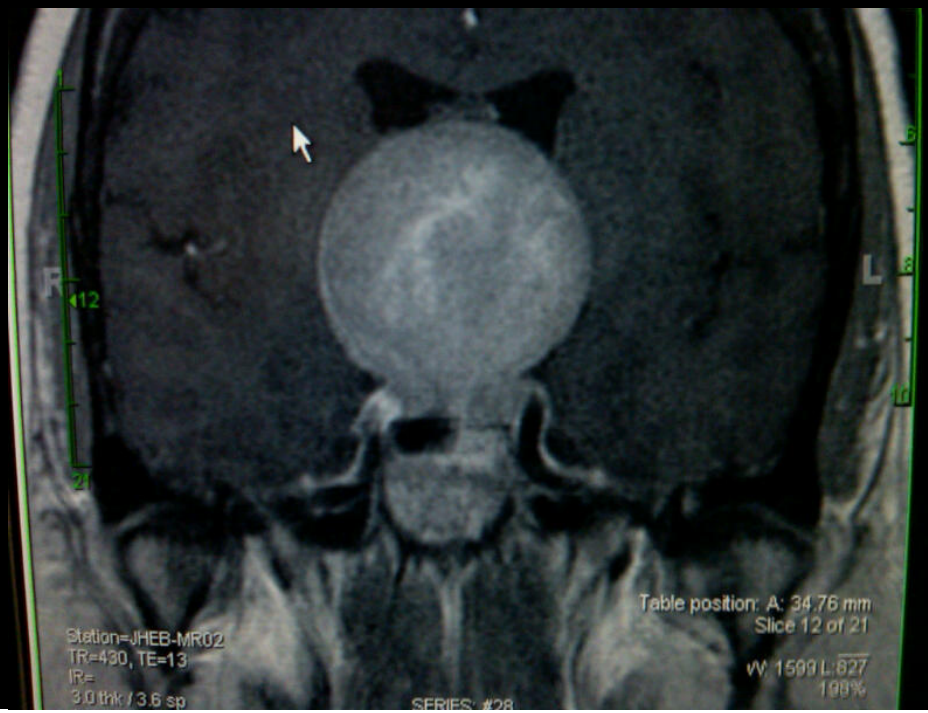
R
L
12
21
Station=JHEB-MR02
TR=430, TE=13
IR=
3.0 thk / 3.6 sp
Table position: A: 34.76 mm
Slice 12 of 21
W: 1599 L: 827
100%
SERIES: #28

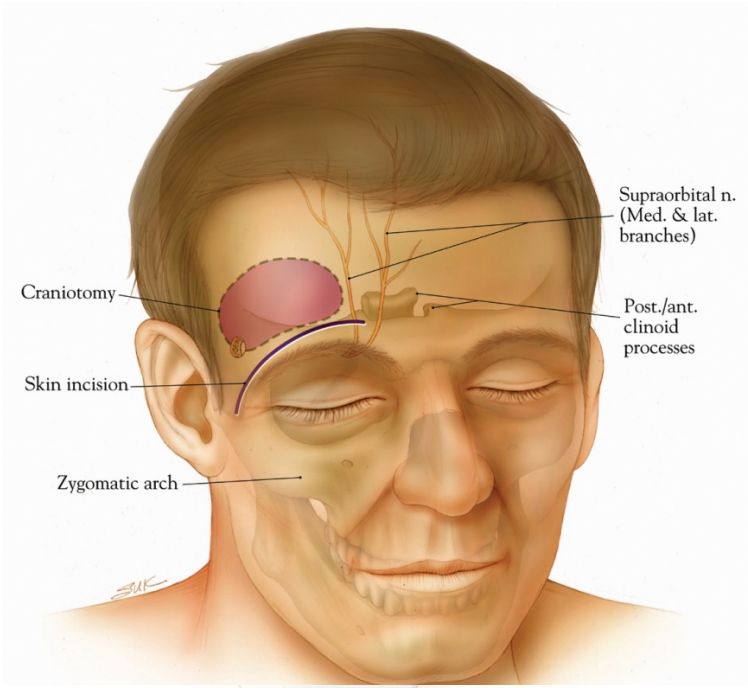
Supraorbital n.
(Med. & lat.
branches)
Craniotomy
Post./ant.
clinoid
processes
Skin incision
Zygomatic arch

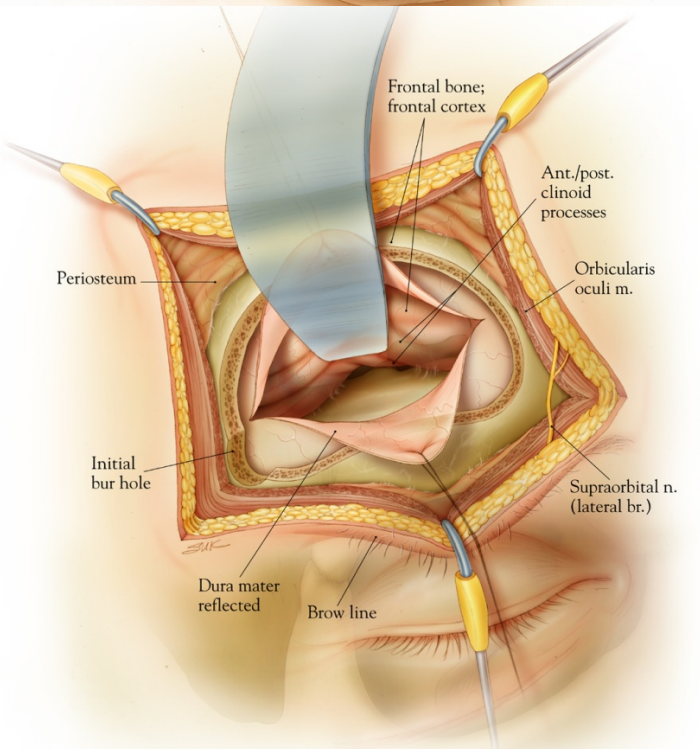
Frontal bone;
frontal cortex
Ant./post.
clinoid
processes
Periosteum
Orbicularis
oculi m.
Initial
bur hole
Supraorbital n.
(lateral br.)
Dura mater
reflected
Brow line

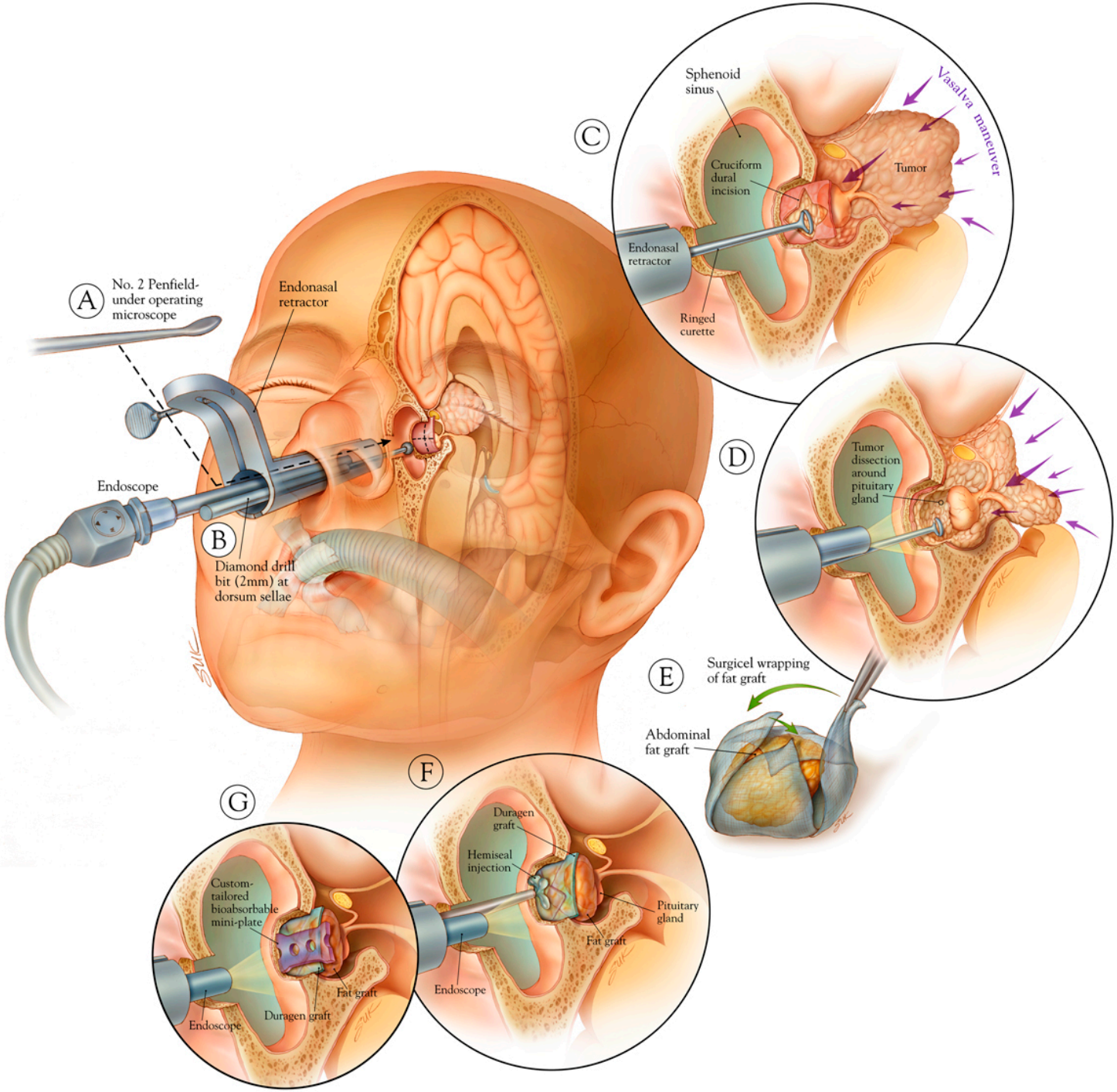
A
No. 2 Penfield-
under operating
microscope
Endonasal
retractor
Endoscope
B
Diamond drill
bit (2mm) at
dorsum sellae
C
Sphenoid
sinus
Cruciform
dural
incision
Tumor
Vasalva maneuver
Endonasal
retractor
Ringed
curette
D
Tumor
dissection
around
pituitary
gland
E
Surgicel wrapping
of fat graft
Abdominal
fat graft
F
Duragen
graft
Hemiseal
injection
Pituitary
gland
Fat graft
Endoscope
G
Custom-
tailored
bioabsorbable
mini-plate
Fat graft
Duragen graft
Endoscope

Intraaxial tumors:

- LGG: JPA, Astrocytoma, Oligodendroglioma
- HGG: Grade III Astrocytoma, Anaplastic Oligodendroglioma, GBM

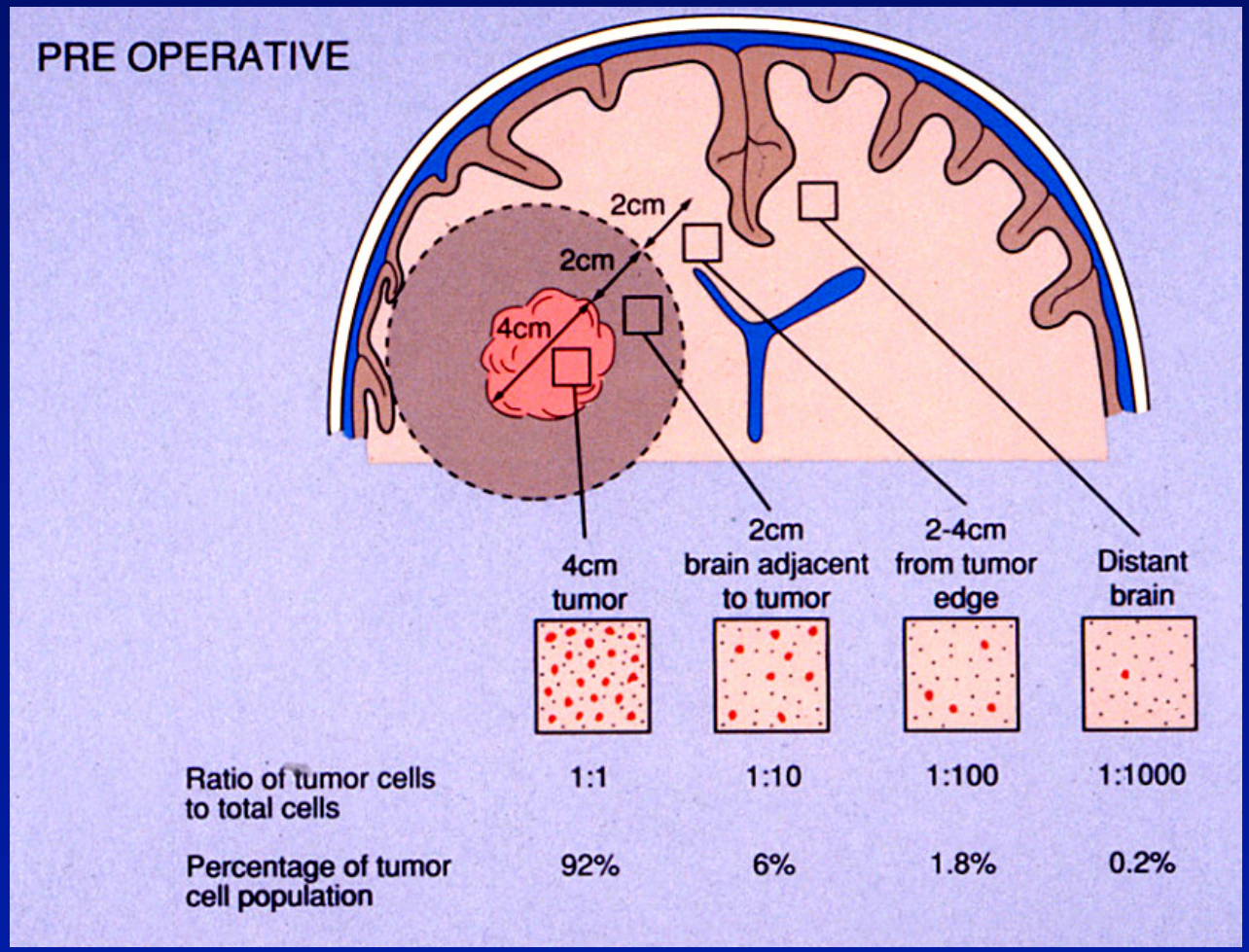

At diagnosis $10^8 – 10^{10}$ cells

Extent of Resection and Survival after Resection of Low Grade Astrocytoma

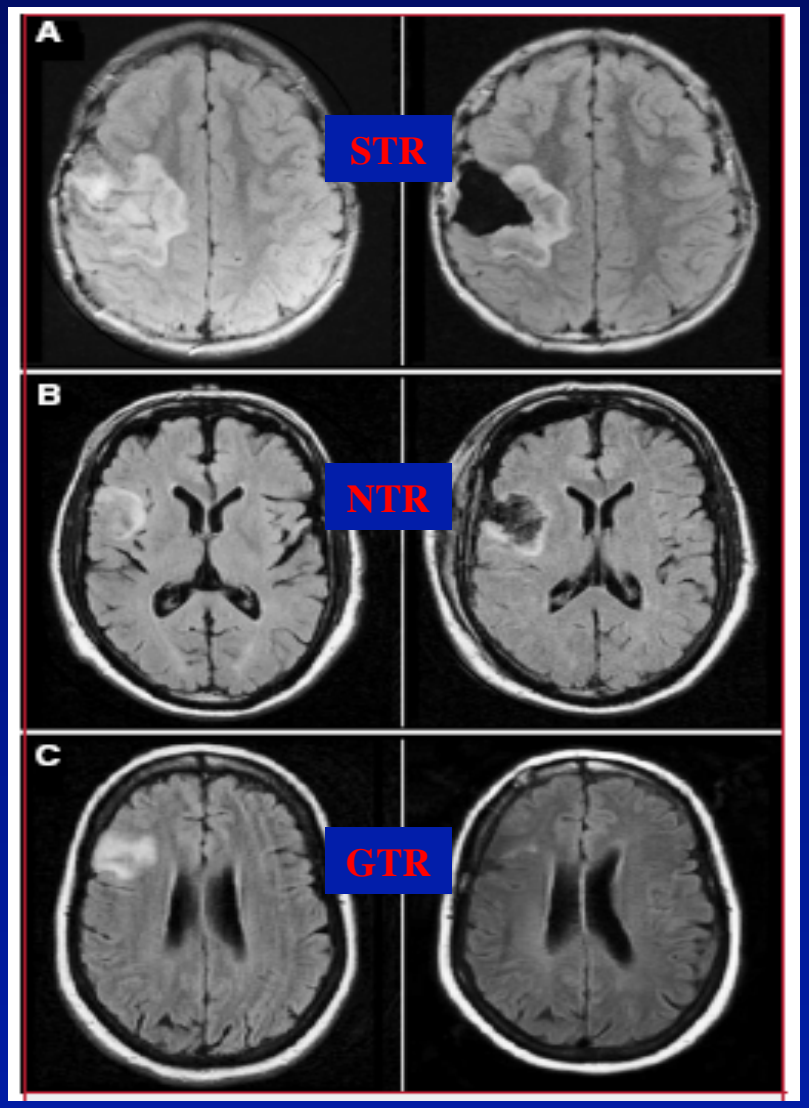

Neurosurgery 63(4):700-7, 2008

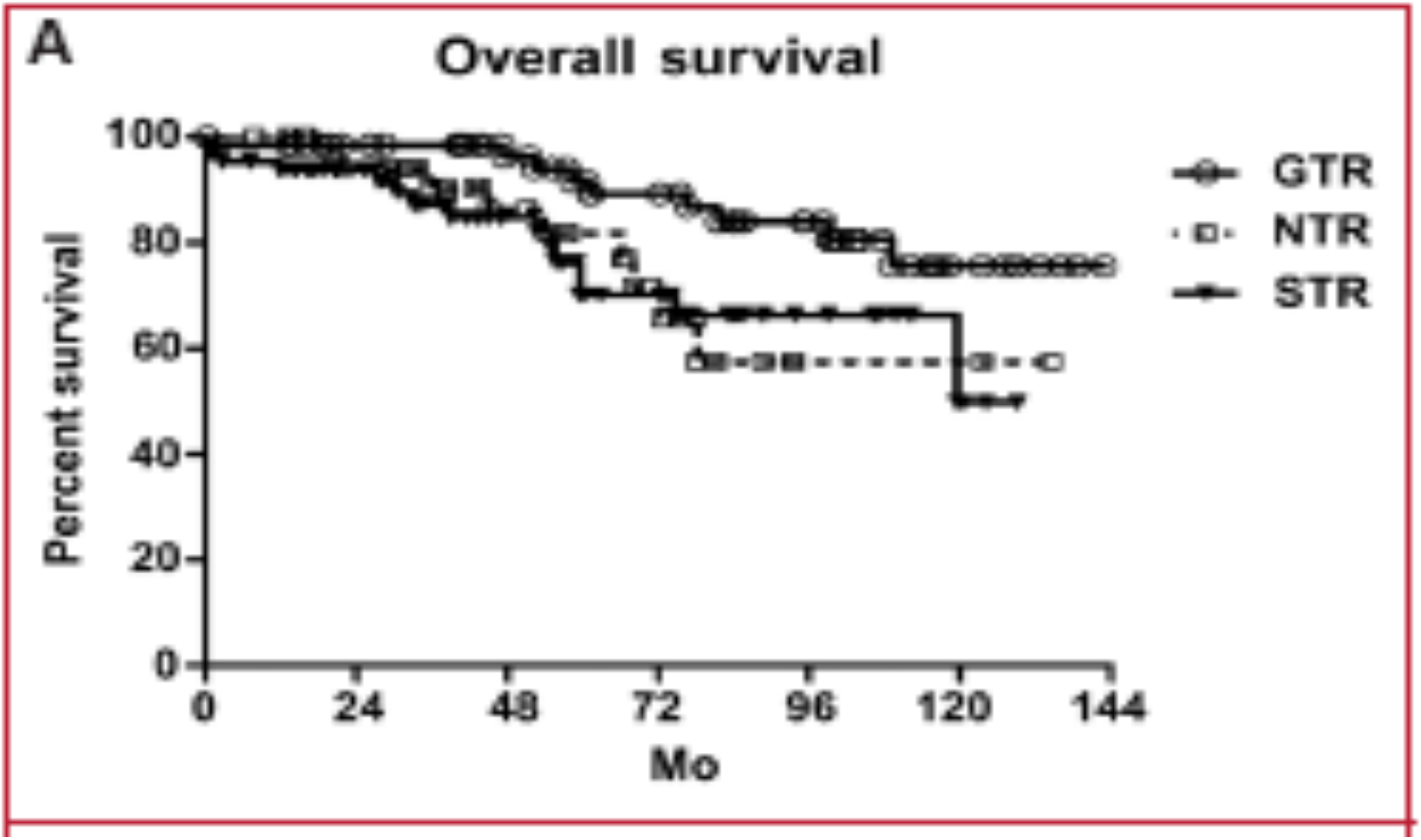
A
Overall survival
Percent survival
100
80
60
40
20
0
0
24
48
72
96
120
144
Mo
GTR
NTR
STR

Perspective: Glioblastoma Multiforme (GBM)

- Walker et al (J Neurosurg, 1978) reported a median survival of 10 months
- Stupp et al (NEJM, 2005) median survival of 14.6 months

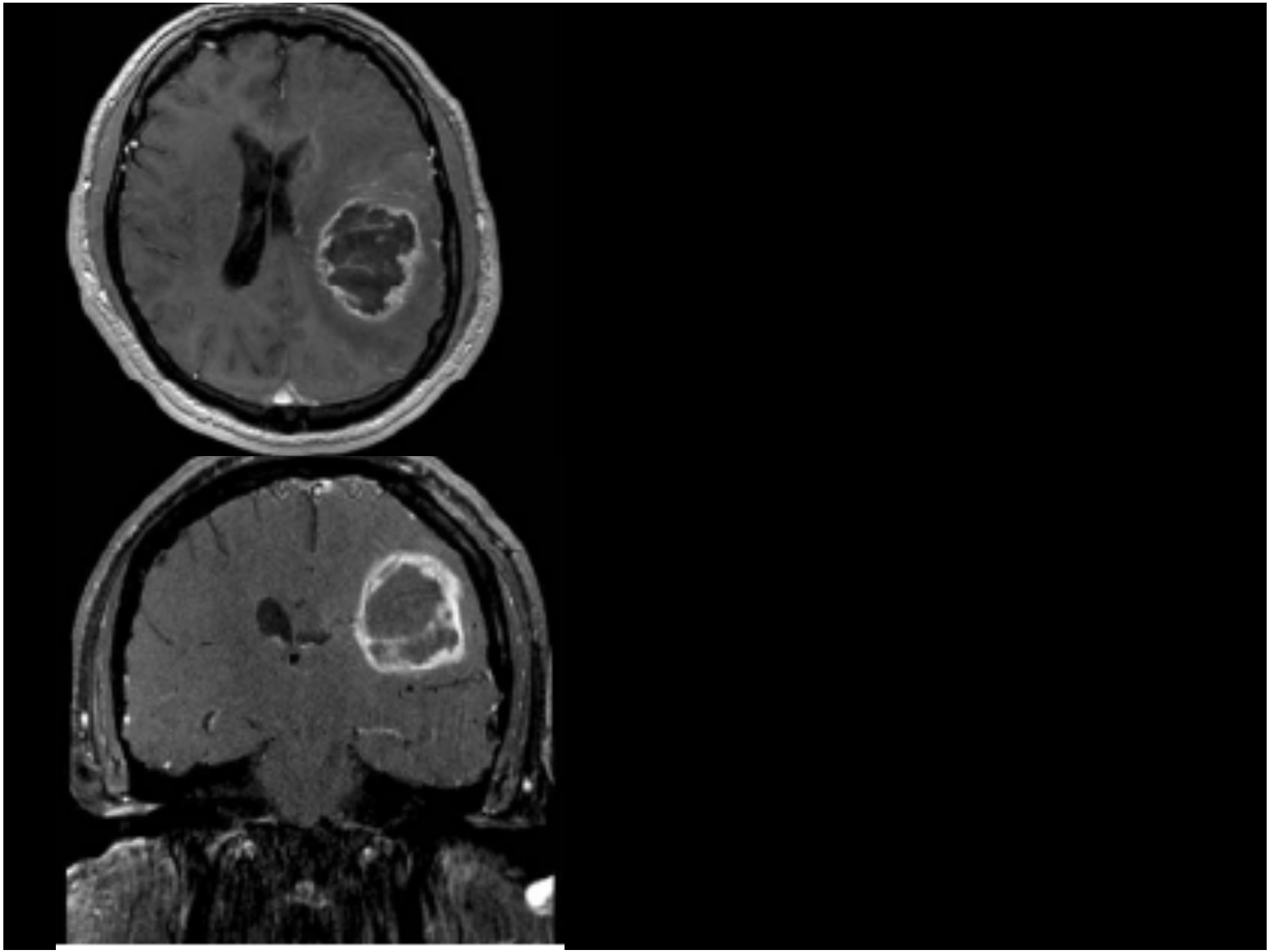

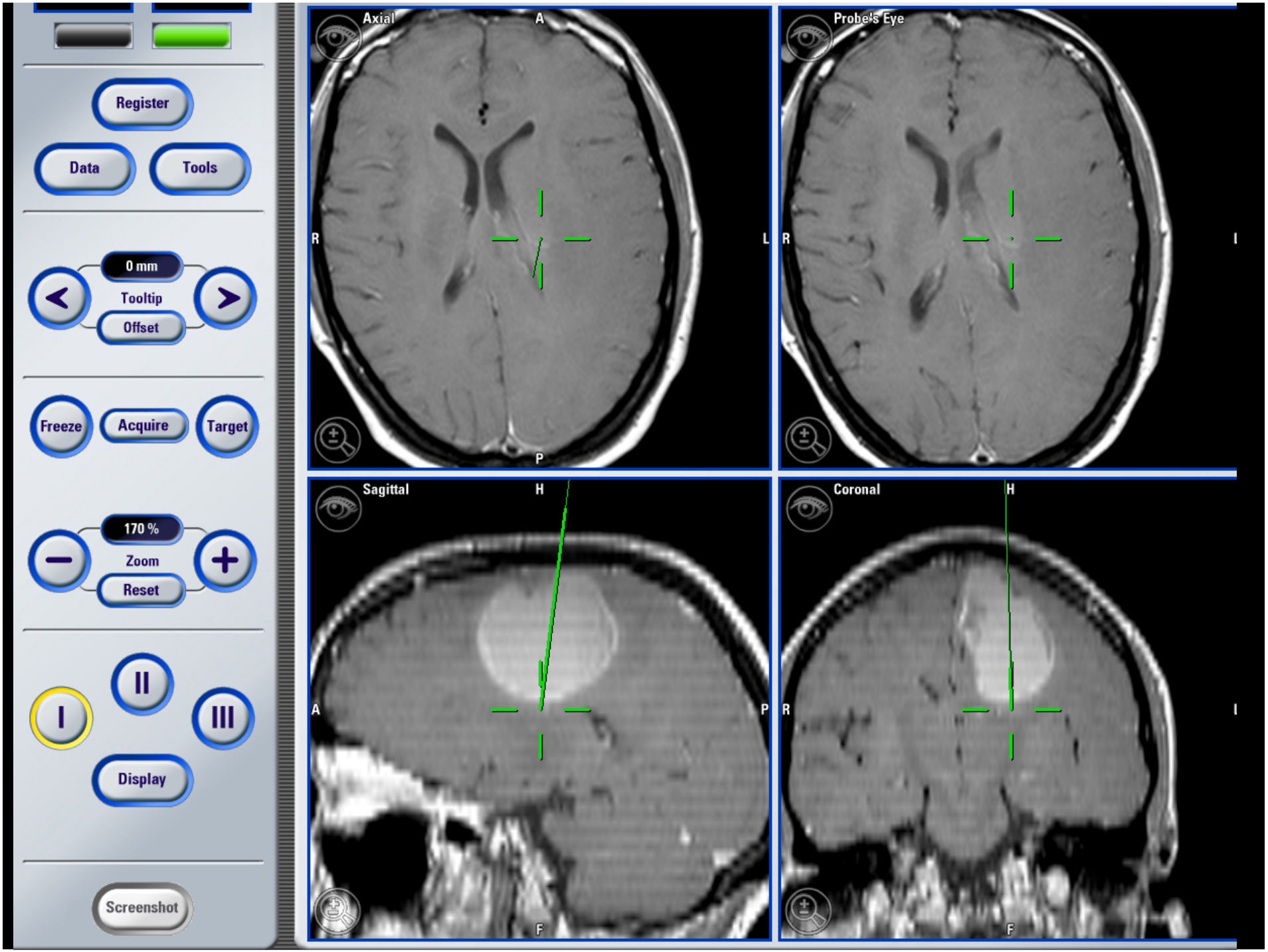
Register
Data
Tools
0 mm
Tooltip
Offset
Freeze
Acquire
Target
170 %
Zoom
Reset
I
II
III
Display
Screenshot
Axial
A
R
L
P
Probe's Eye
R
I
Sagittal
H
A
P
F
Coronal
H
R
I
F

Intraop Movie: Motor Mapping

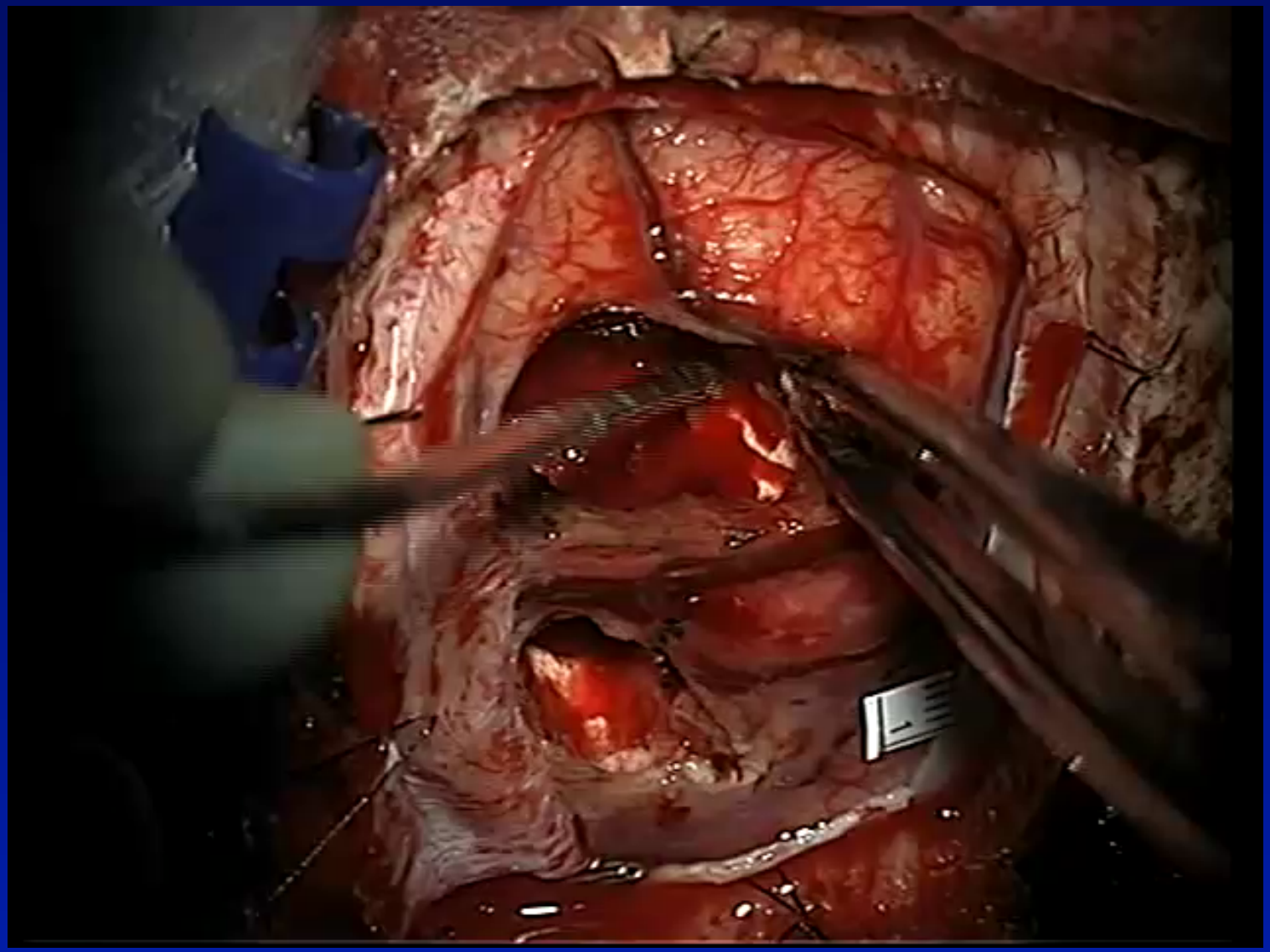

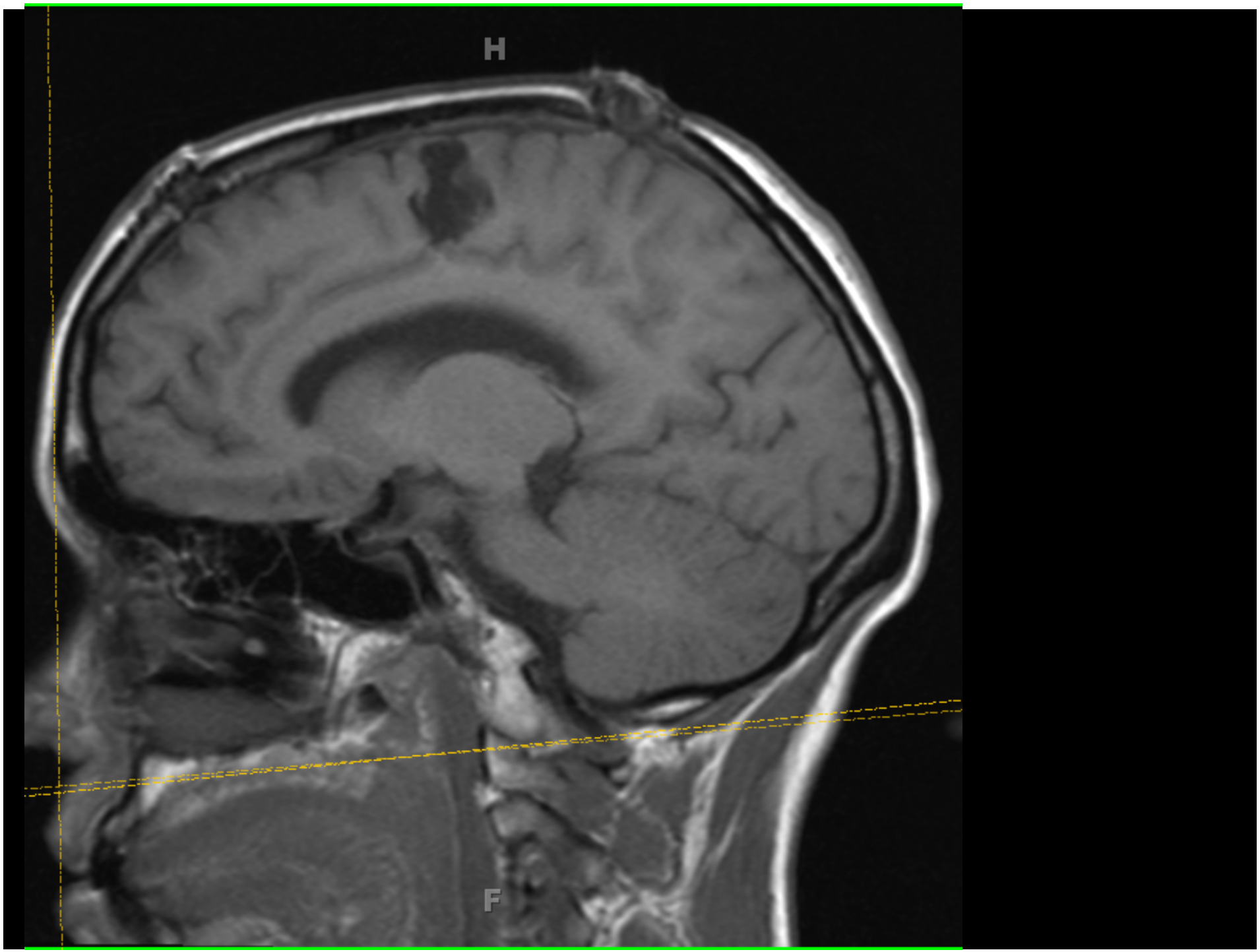
H
F

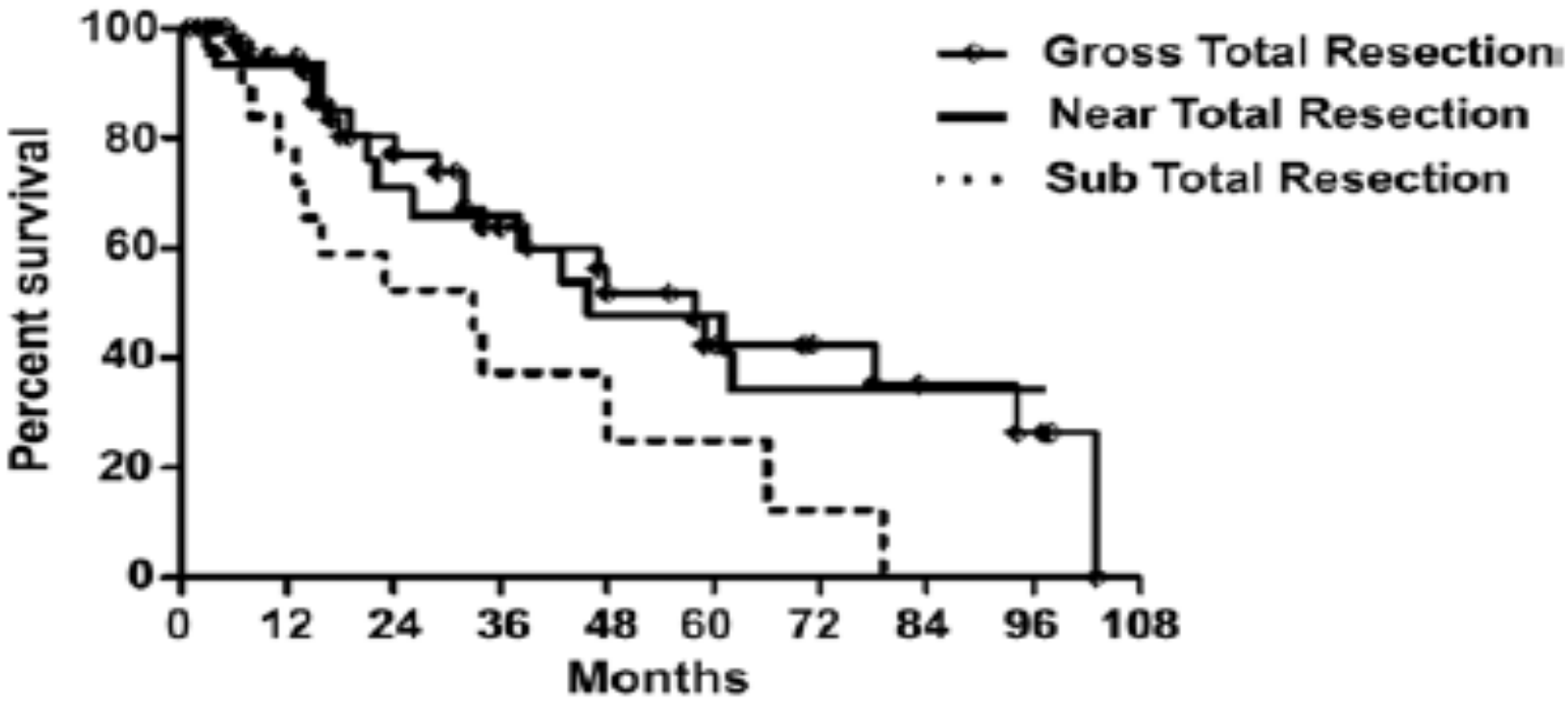

FIG. 2. Estimated Kaplan–Meier plot of survival after primary resection of AAs (mixed oligoastrocytoma excluded). Both GTR and NTR were associated with a survival benefit versus STR. Gross-total resection versus NTR was not associated with improved survival. After GTR, NTR, or STR, median survival was 58, 46, and 34 months, respectively. The 5-year survival for patients undergoing GTR, NTR, and STR was 42, 41, and 12%, respectively.

Extent of Resection and Survival after Resection of Malignant Astrocytoma

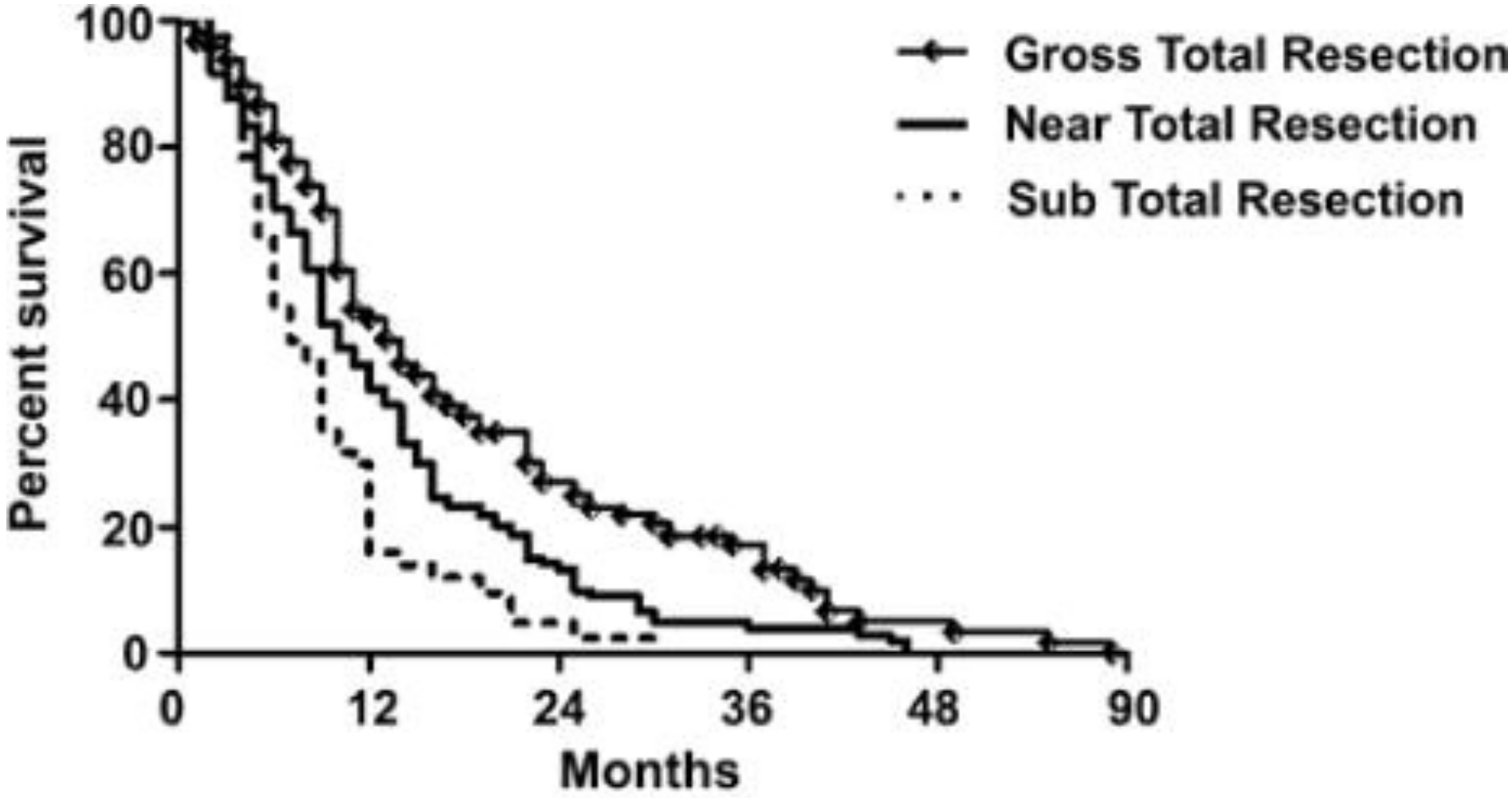

Primary Resection

J Neurosurg **110:**156–162, 2009

Extent of Resection and Survival after Resection of Malignant Astrocytoma

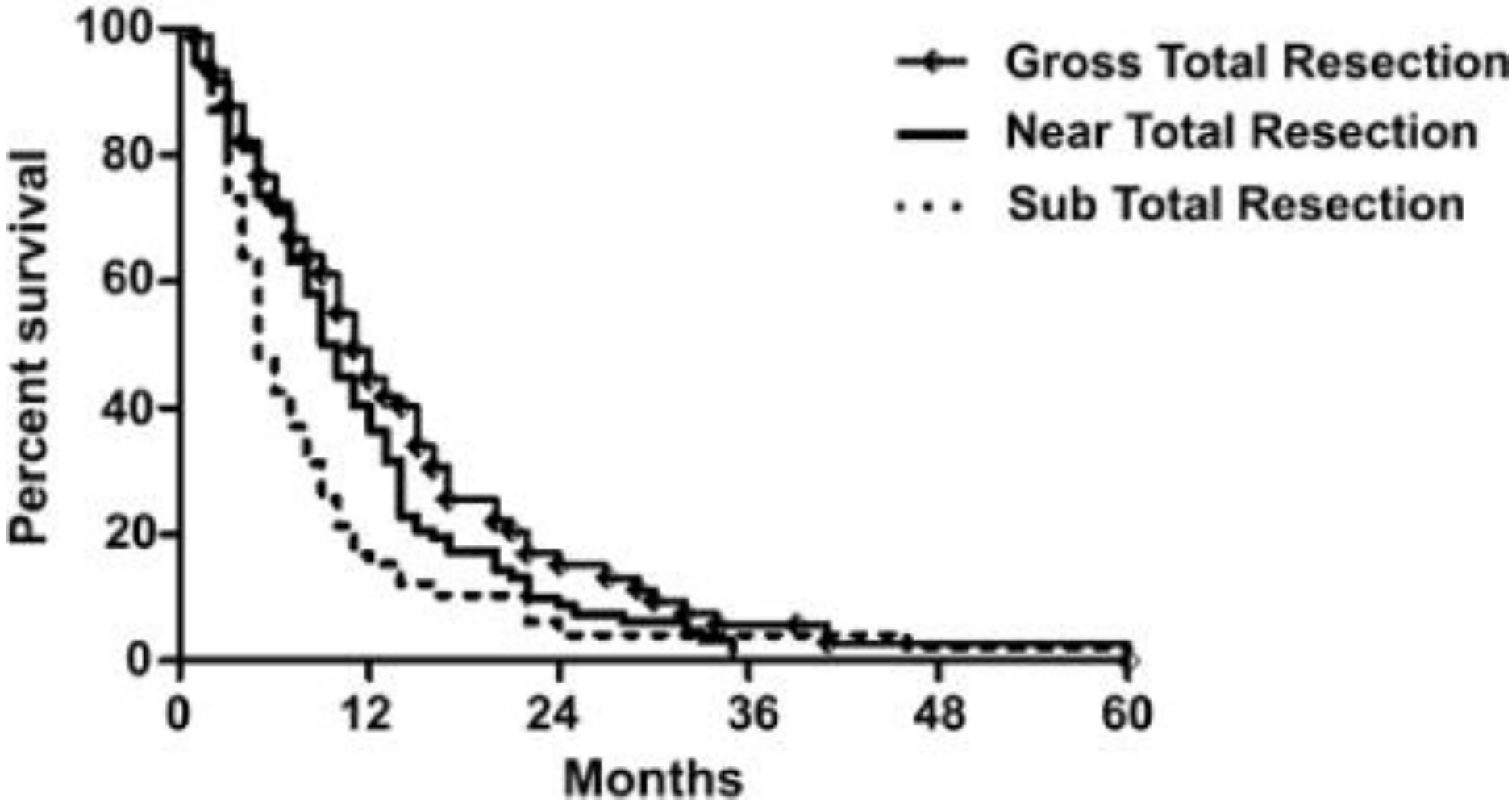

Revision Resection

J Neurosurg **110:**156–162, 2009

If MAXIMAL surgical resection is the goal, then what is the effect on survival for patients with malignant gliomas who acquire surgically induced neurological deficits?

Association of Surgically Acquired Deficits and Survival

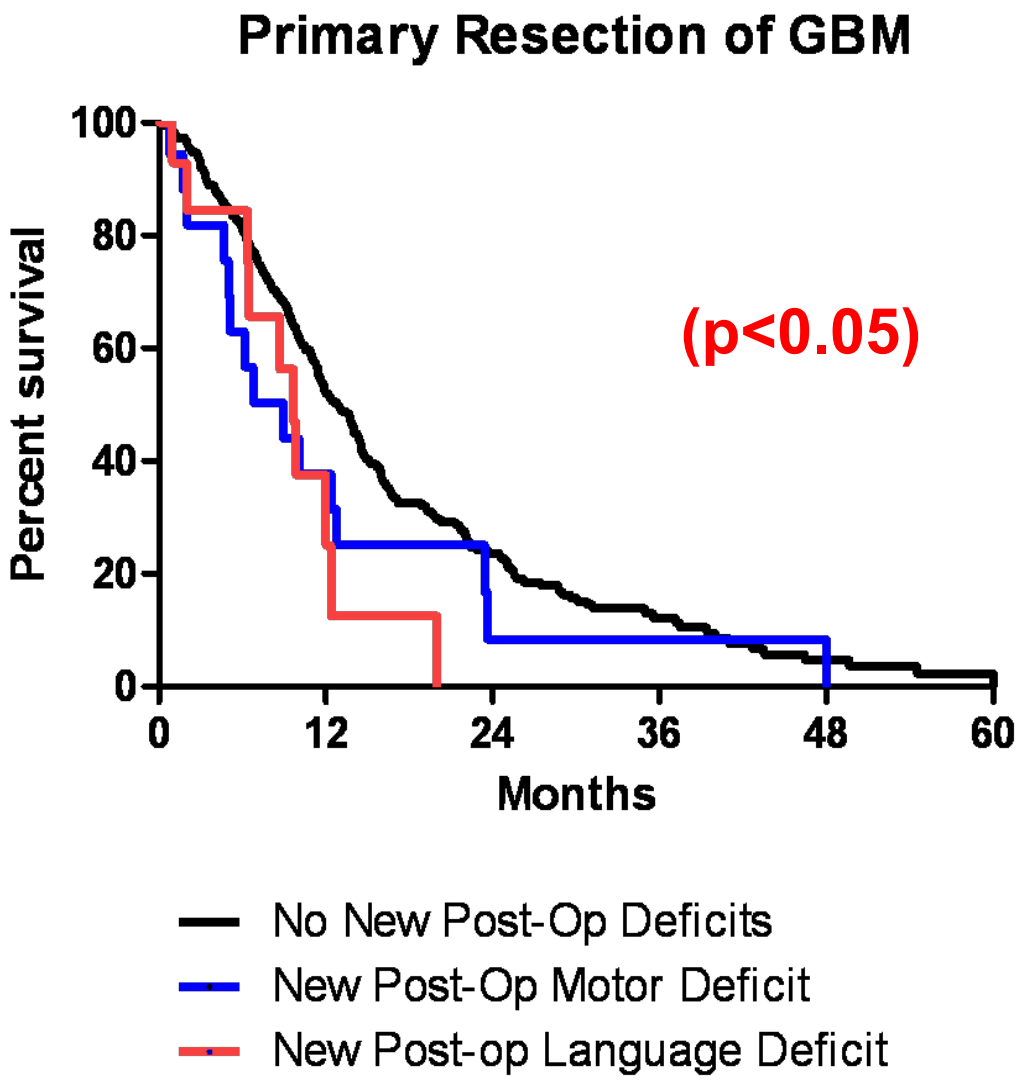

McGirt et al 2010

Intraoperative set up

- **<u>OR set up</u>**
- Surgical navigation
- Draping patient
- EMG Recordings
- Brain Mapping
- Ticket placement

Intraoperative set up

Intraoperative Localization of Motor

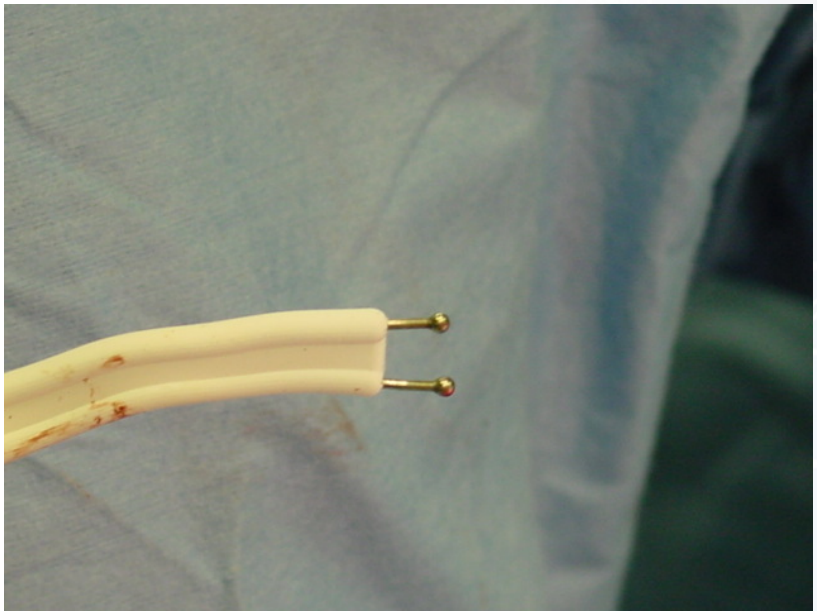

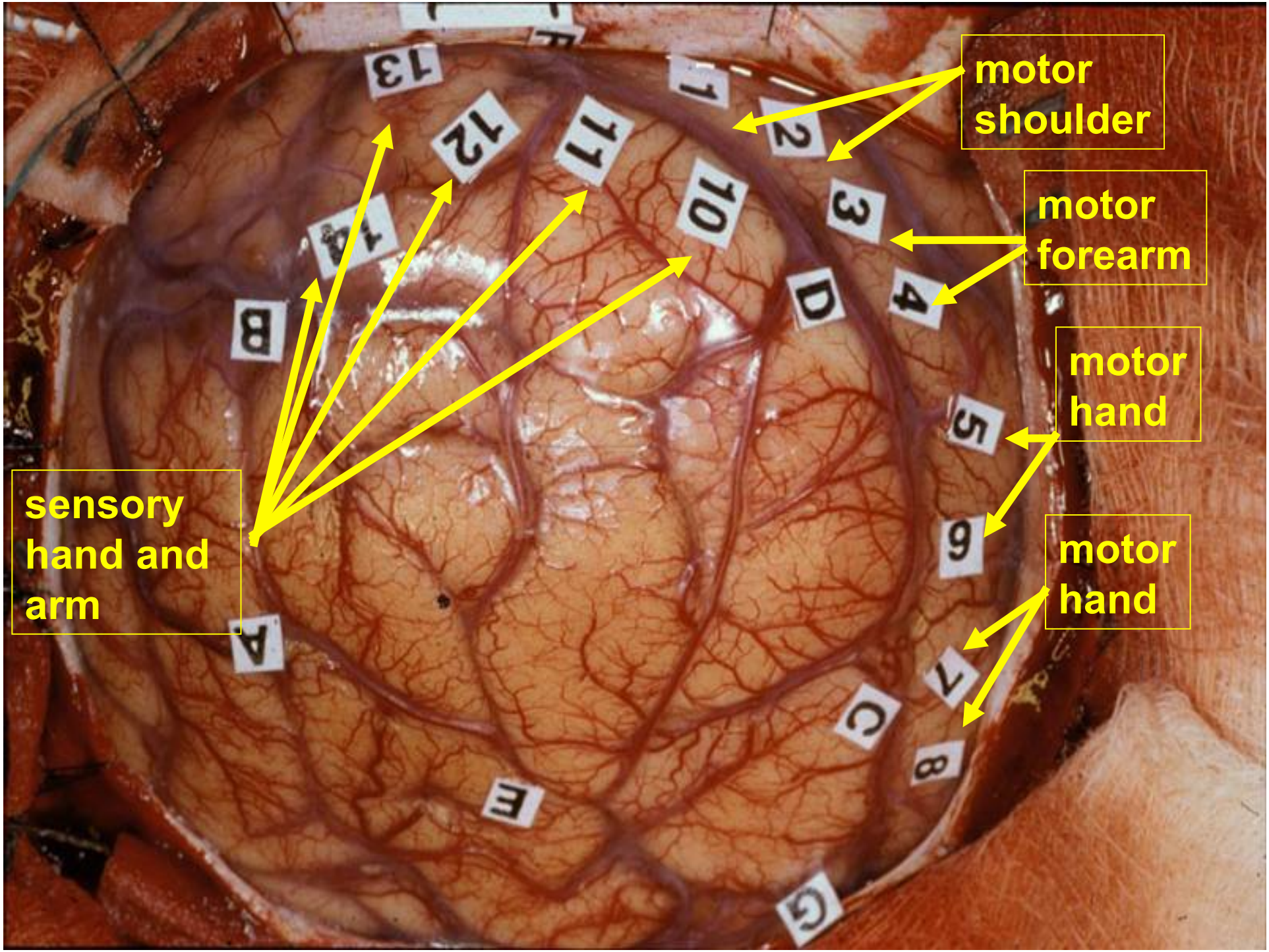
motor shoulder
motor forearm
motor hand
motor hand
sensory hand and arm

DTI: Subcortical White Matter Tracts

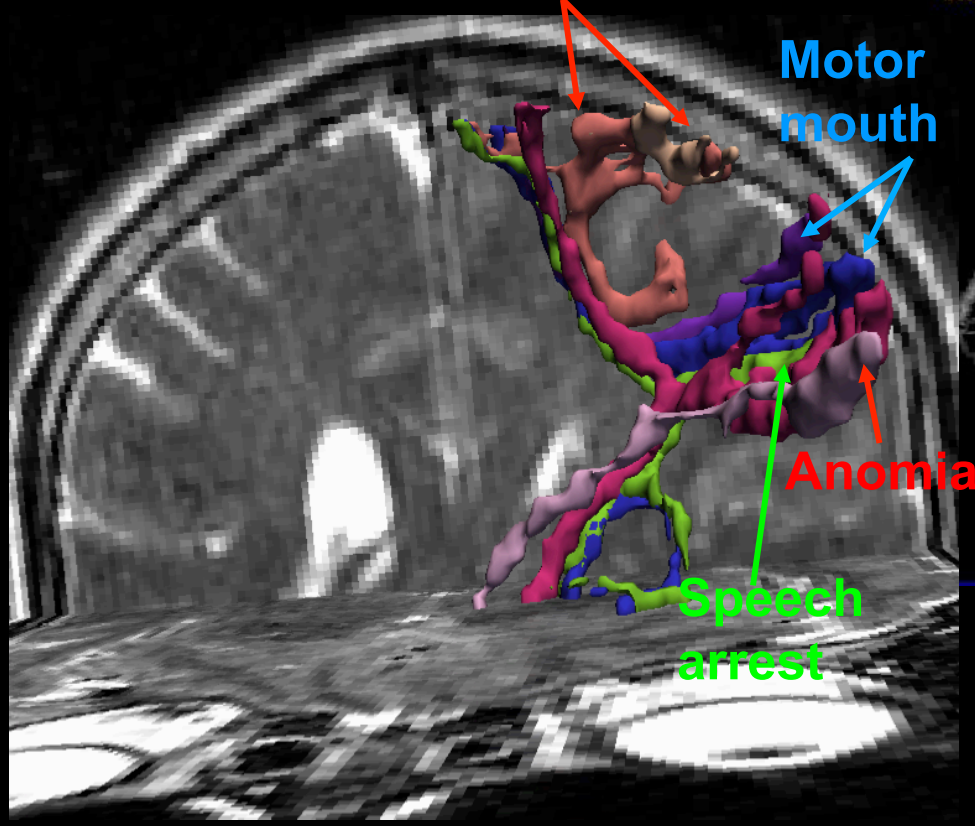

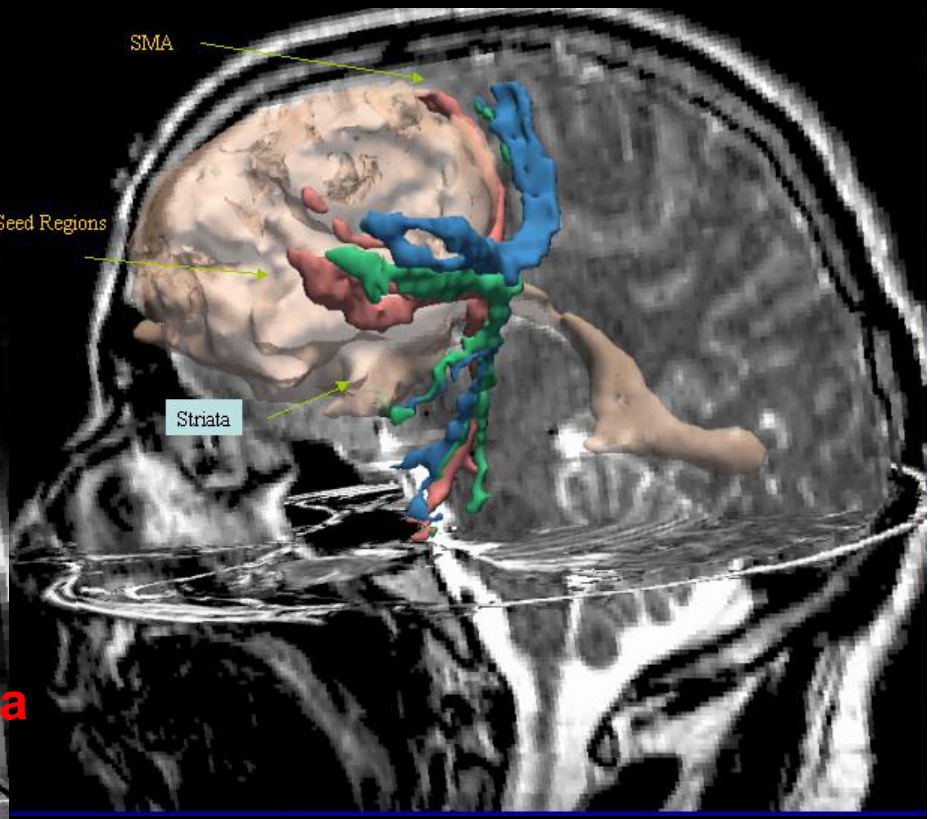

Neuroimage, 2004



Speech Mapping: Awake

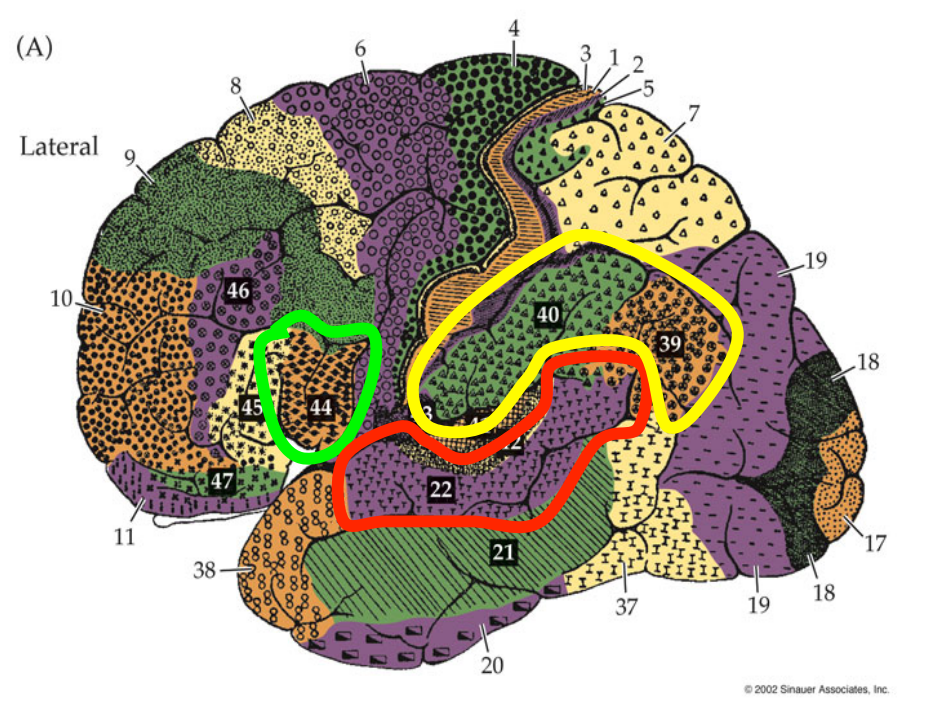

fMRI

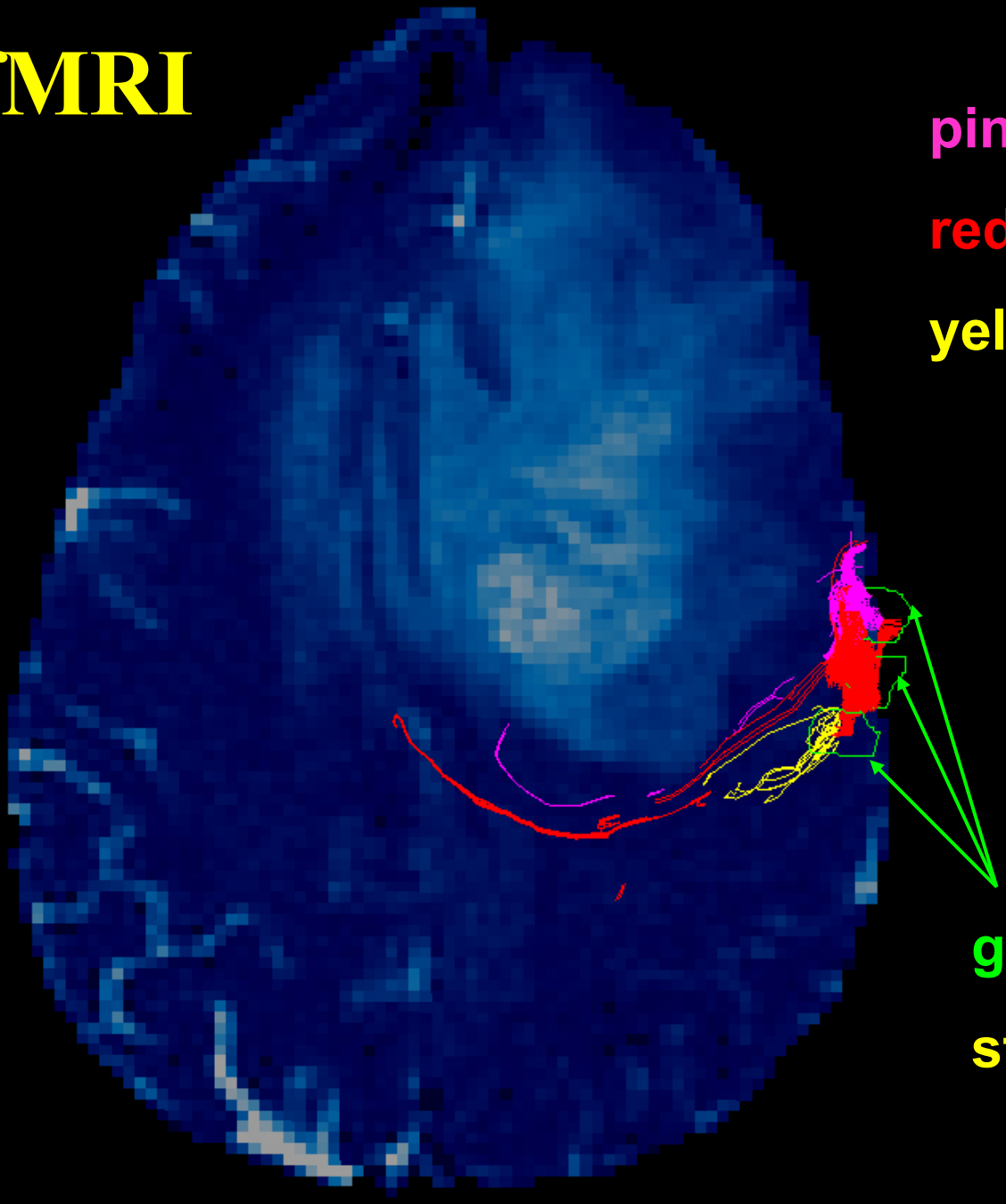

pink: anomia

red: speech arrest

yellow: mouth motor

green: cortical stimulation sites

PATIENT	AGE	SEX	Tumor Location	Tumor Type	Languages	Age at Acquisition	Cortical Representation
1	39	F	L Temporal	Astrocytoma	Chinese English	Infant 5 Yrs	2 sites arrested both languages

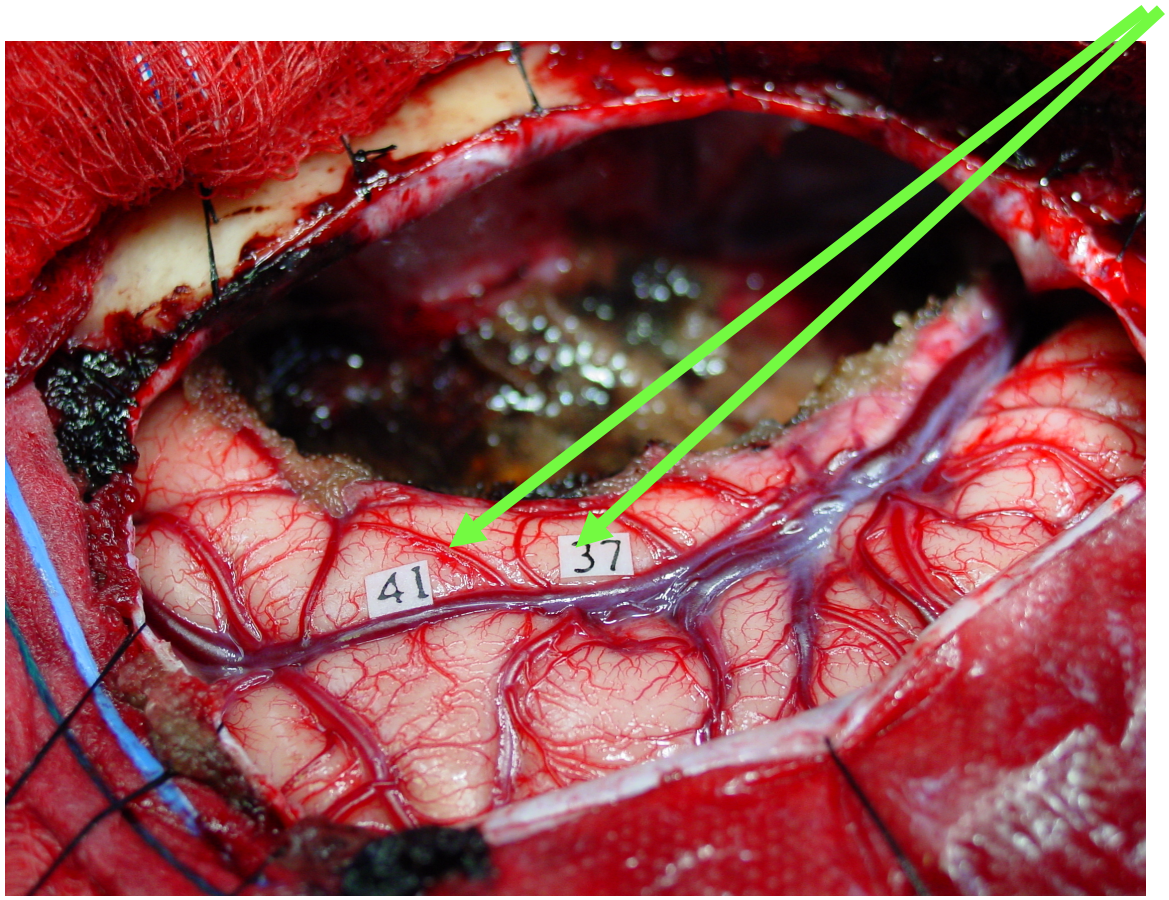

Quinones-Hinojosa et al Neurosurgery, 2004

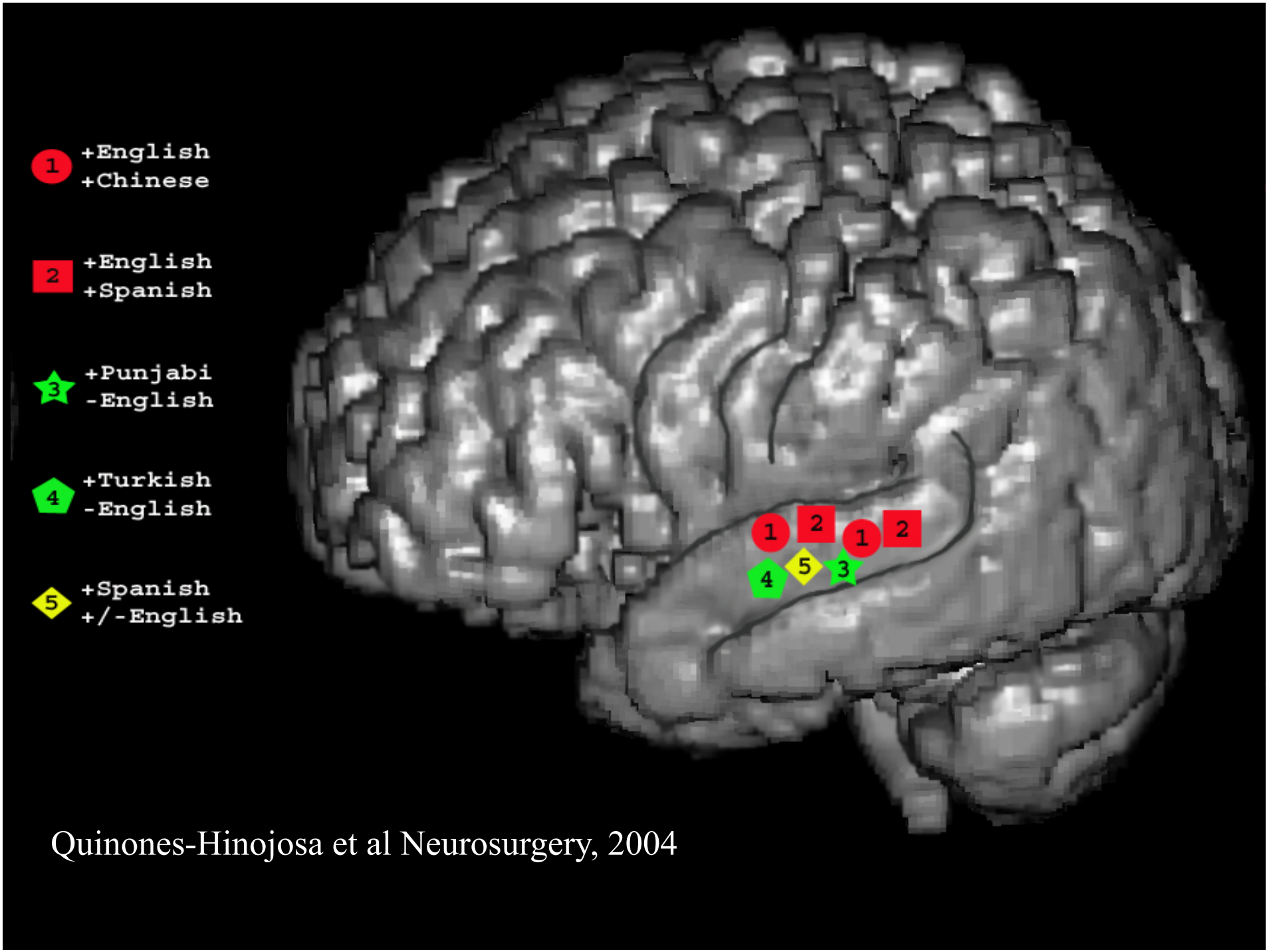

Quinones-Hinojosa et al Neurosurgery, 2004

The NEW ENGLAND JOURNAL of MEDICINE

ORIGINAL ARTICLE

Radiotherapy plus Concomitant and Adjuvant Temozolomide for Glioblastoma

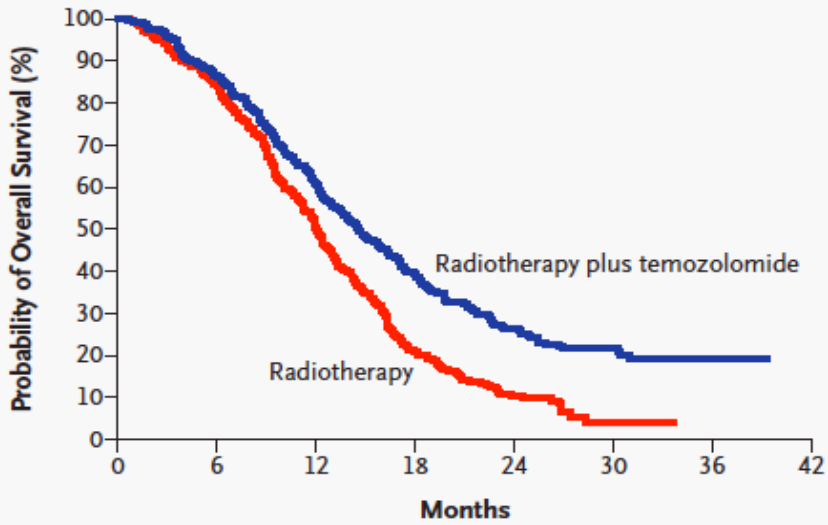

No. at Risk							
Radiotherapy	286	240	144	59	23	2	0
Radiotherapy plus temozolomide	287	246	174	109	57	27	4

Figure 1. Kaplan–Meier Estimates of Overall Survival According to Treatment Group.

The hazard ratio for death among patients treated with radiotherapy plus temozolomide, as compared with those who received radiotherapy alone, was 0.63 (95 percent confidence interval, 0.52 to 0.75; P<0.001).

R. Stupp et al, 2005

Table 1. Summary of Current Treatments for Malignant Gliomas.*

Type of Tumor	Therapy
Newly diagnosed tumors	
Glioblastomas (WHO grade IV)	Maximal surgical resection, plus radiotherapy, plus concomitant and adjuvant TMZ or carmustine wafers (Gliadel)†
Anaplastic astrocytomas (WHO grade III)	Maximal surgical resection, with the following options after surgery (no accepted standard treatment): radiotherapy, plus concomitant and adjuvant TMZ or adjuvant TMZ alone†
Anaplastic oligodendrogliomas and anaplastic oligoastrocytomas (WHO grade III)	Maximal surgical resection, with the following options after surgery (no accepted standard treatment): radiotherapy alone, TMZ or PCV with or without radiotherapy afterward, radiotherapy plus concomitant and adjuvant TMZ, or radiotherapy plus adjuvant TMZ†‡
Recurrent tumors	Reoperation in selected patients, carmustine wafers (Gliadel), conventional chemotherapy (e.g., lomustine, carmustine, PCV, carboplatin, irinotecan, etoposide), bevacizumab plus irinotecan, experimental therapies‡

Overall Survival after Resection of GBM at the Johns Hopkins Hospital

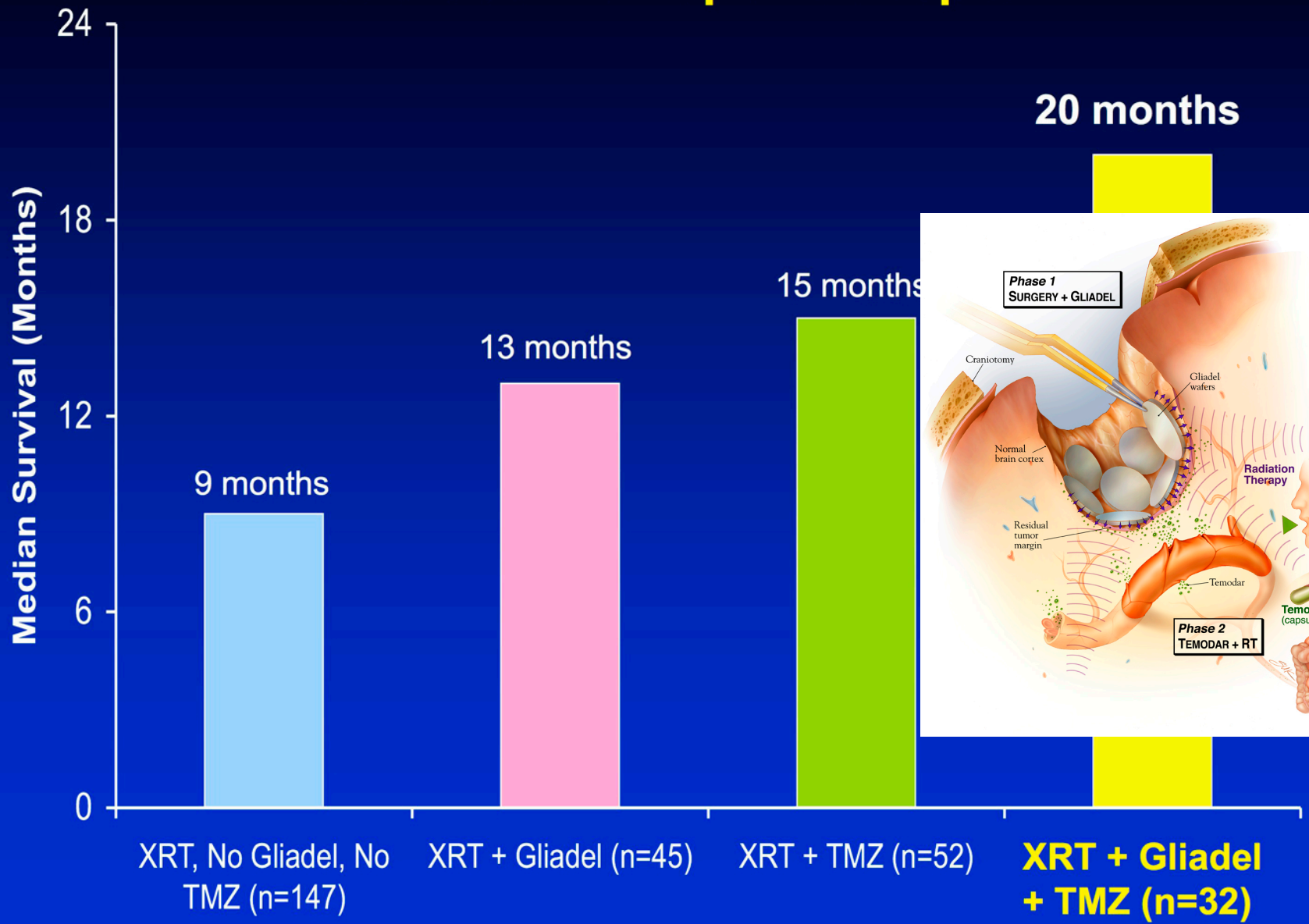

Quinones-Hinojosa et al , 2009

Cell-of-Origin: Differentiated Glial or Stem or Progenitor Cells

Wen and Kesari, NEJM 2008

Olig2 expression (100%)
LOH 1p, 4q, 19q
EGFR overexpressed
PDGF/PDGFR overexpressed

Low-Grade Oligodendroglioma (5–10 yr)*
(WHO Grade II)

P16Ink4a/P14ARF loss
RB mutated (~65%)
p53 mutated
PTEN loss
LOH 9p, 10q
CDK4/EGFR/MYC amplified
VEGF overexpressed

Anaplastic Oligodendroglioma (3–5 yr)*
(WHO Grade III)

Cell-of-Origin: Differentiated Glial or Stem or Progenitor Cells

Wen and Kesari, NEJM 2008

Olig2 expression (100%)
EGFR amplified (~40%)
EGFR overexpressed (~60%)
EGFR mutated (~20–30%)
MDM2 amplified (~10%)
MDM2 overexpressed (>50%)
LOH 10q (~70%)
P16Ink4a/P14ARF loss (~30%)
PTEN mutated (~40%)
PI3K mutated/amplified (~20%)
RB mutated
VEGF overexpressed

Primary Glioblastoma (12–15 mo)*
(WHO Grade IV)

Cell-of-Origin: Differentiated Glial or Stem or Progenitor Cells

Wen and Kesari, NEJM 2008

Olig2 expression (100%)
P53 mutated (>65%)
PDGFA/PDGFR-α overexpressed (~60%)

Low-Grade Astrocytoma (5–10 yr)*
(WHO Grade II)

LOH 19q (~50%)
RB mutated (~25%)
CDK4 amplified (15%)
MDM2 overexpressed (10%)
P16Ink4a/P14ARF loss (4%)
LOH 11p (~30%)

Anaplastic Astrocytoma (2–3 yr)*
(WHO Grade III)

LOH 10q (~70%)
DCC loss (~50%)
PDGFR-α amplified (~10%)
PTEN mutated (~10%)
PI3K mutated/amplified (~10%)
VEGF overexpressed

Secondary Glioblastoma (12–15 mo)*
(WHO Grade IV)

19 February 2004

International weekly journal of science

nature

$10.00

www.nature.com/nature

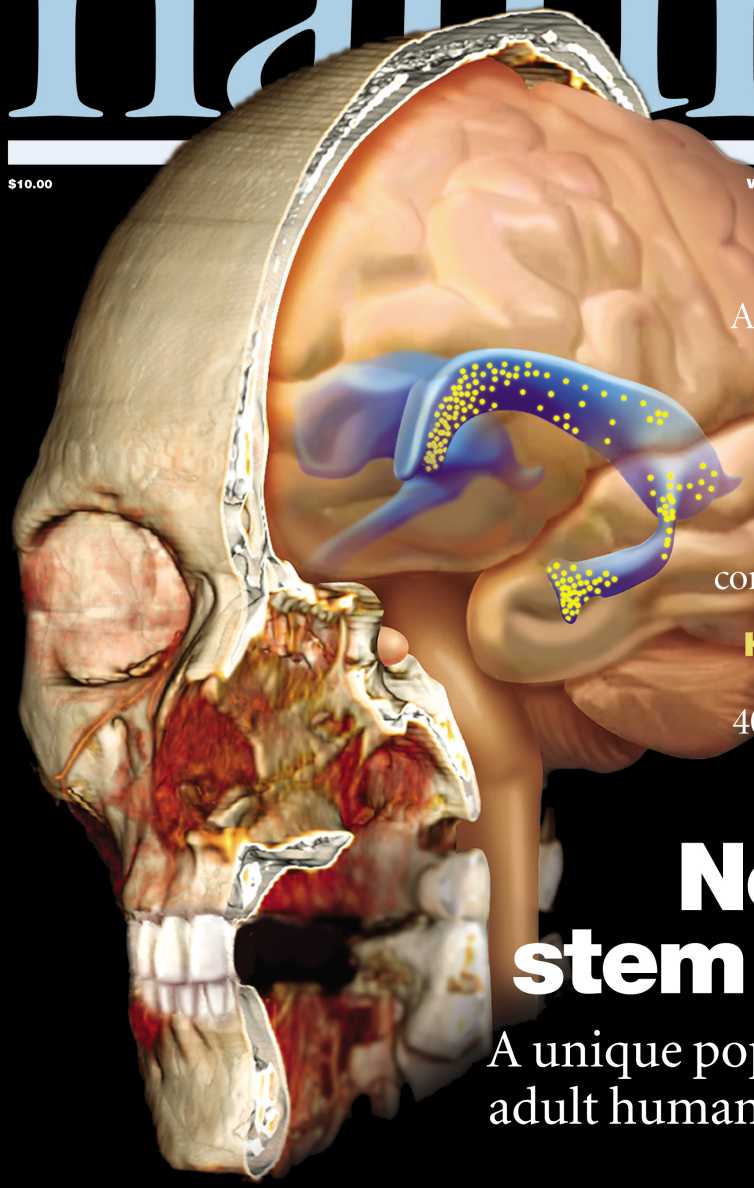

The Assisi earthquake
Aftershocks were fluid driven

My name is LUCA
Unveiling the last universal common ancestor

Homokaryosis
How to survive 400 million years without sex

Neural stem cells

A unique population of adult human astrocytes

Brain Tumor Stem Cells

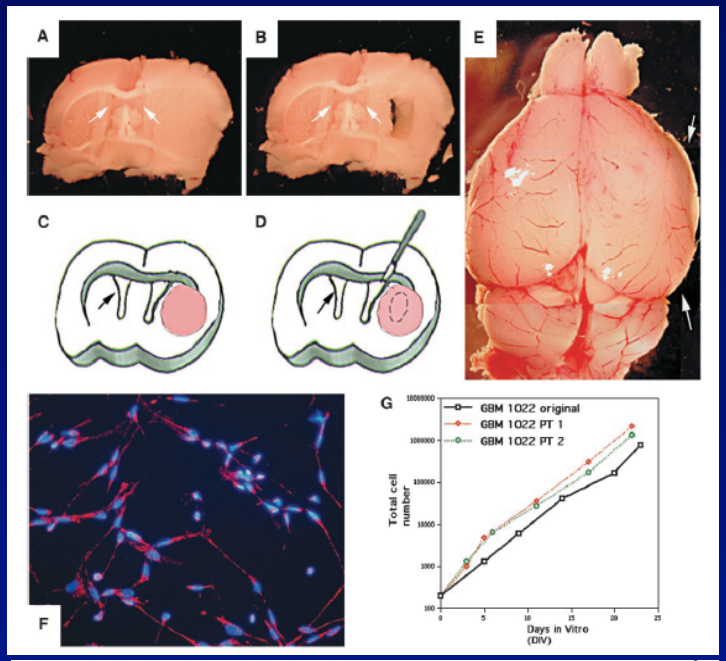

Galli et al.

Cancer Res, 2004

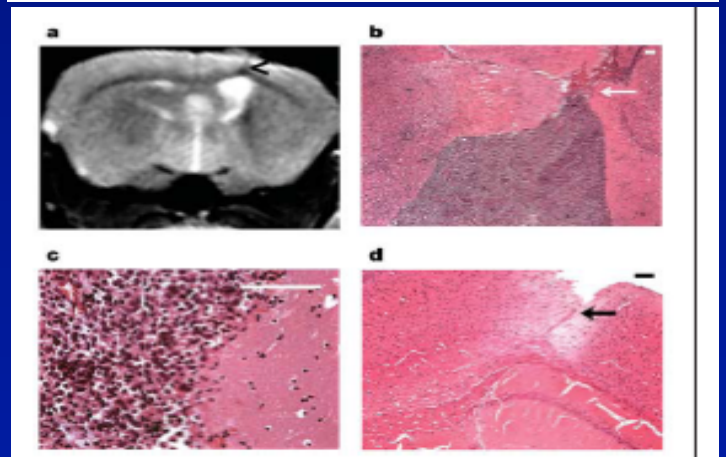

Figure 1 CD133$^+$ tumour cells initiate tumours upon intracranial transplantation into the adult NOD-SCID mouse forebrain. a, Magnetic resonance imaging (MRI) scan of a mouse injected with 1,000 CD133$^+$ medulloblastoma cells shows an enhancing mass under the injection tract (arrowheads) 14 weeks post-injection. b, c, Low (b) and high (c) magnification histological sections of the xenograft show a highly cellular mass below the injection site (white arrow in b). d, Histological section of mouse brain injected with CD133$^-$ medulloblastoma cells shows the injection tract (black arrow), but no tumour formation. Scale bar on all panels represents 100 microns.

Singh et al.

Nature, 2004

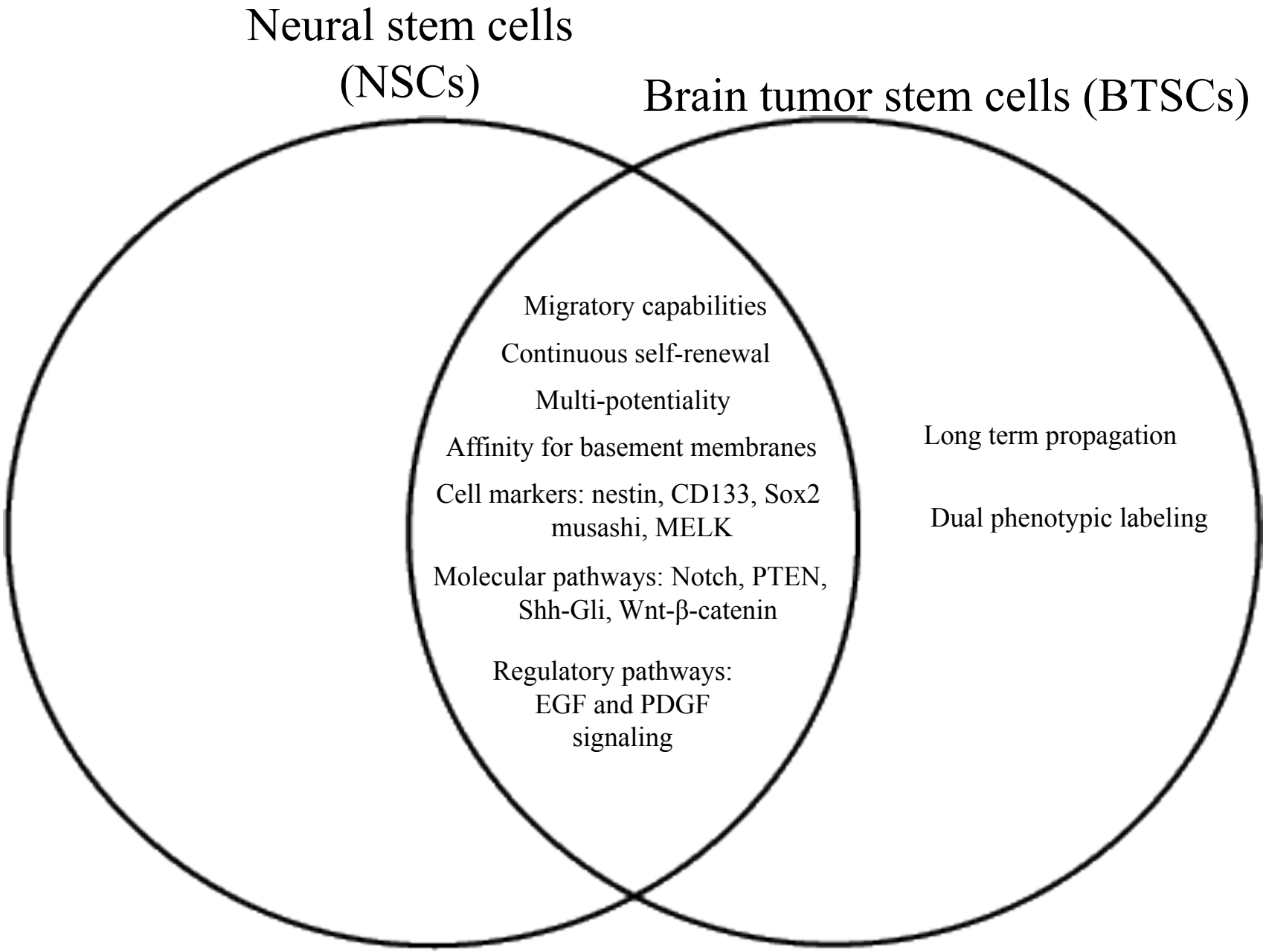

Quinones and Chaichana, Exp Neurol 2007

Brain Tumors: Conclusions

- Little over 100 years since brain surgery for tumors started
- Noncancerous vs Cancerous
- Cancerous:
  - Low vs High Grade
  - Primary vs secondary
  - Mutations
- Surgery: Mapping, Navigation, Awake cranis
- Brain tumor dispersal still a challenge
- Appears to be population of cancer stem cells in malignant brain tumors

Rodent Brain

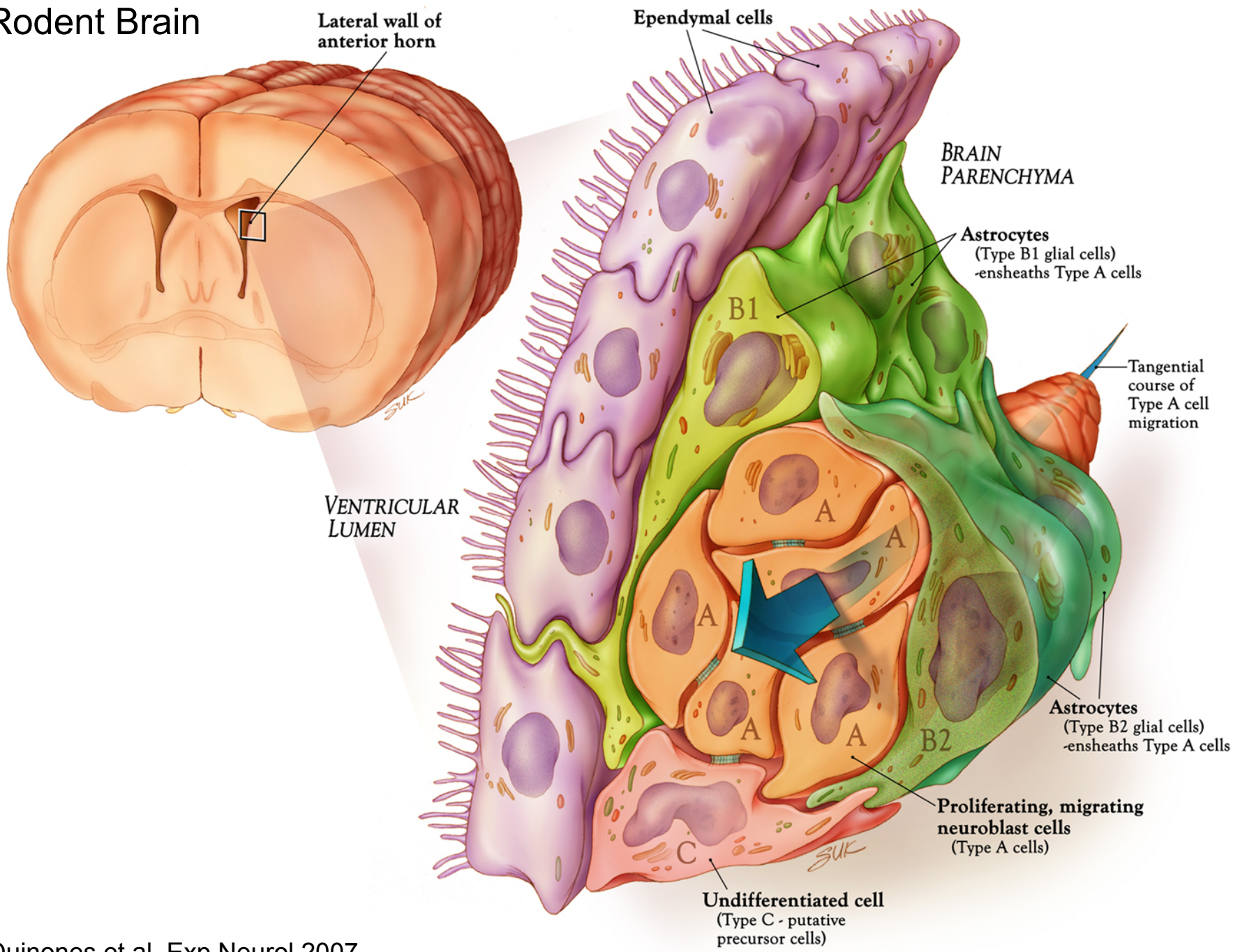

Quinones et al, Exp Neurol 2007

Could the SVZ be the origin of some Brain Tumors?

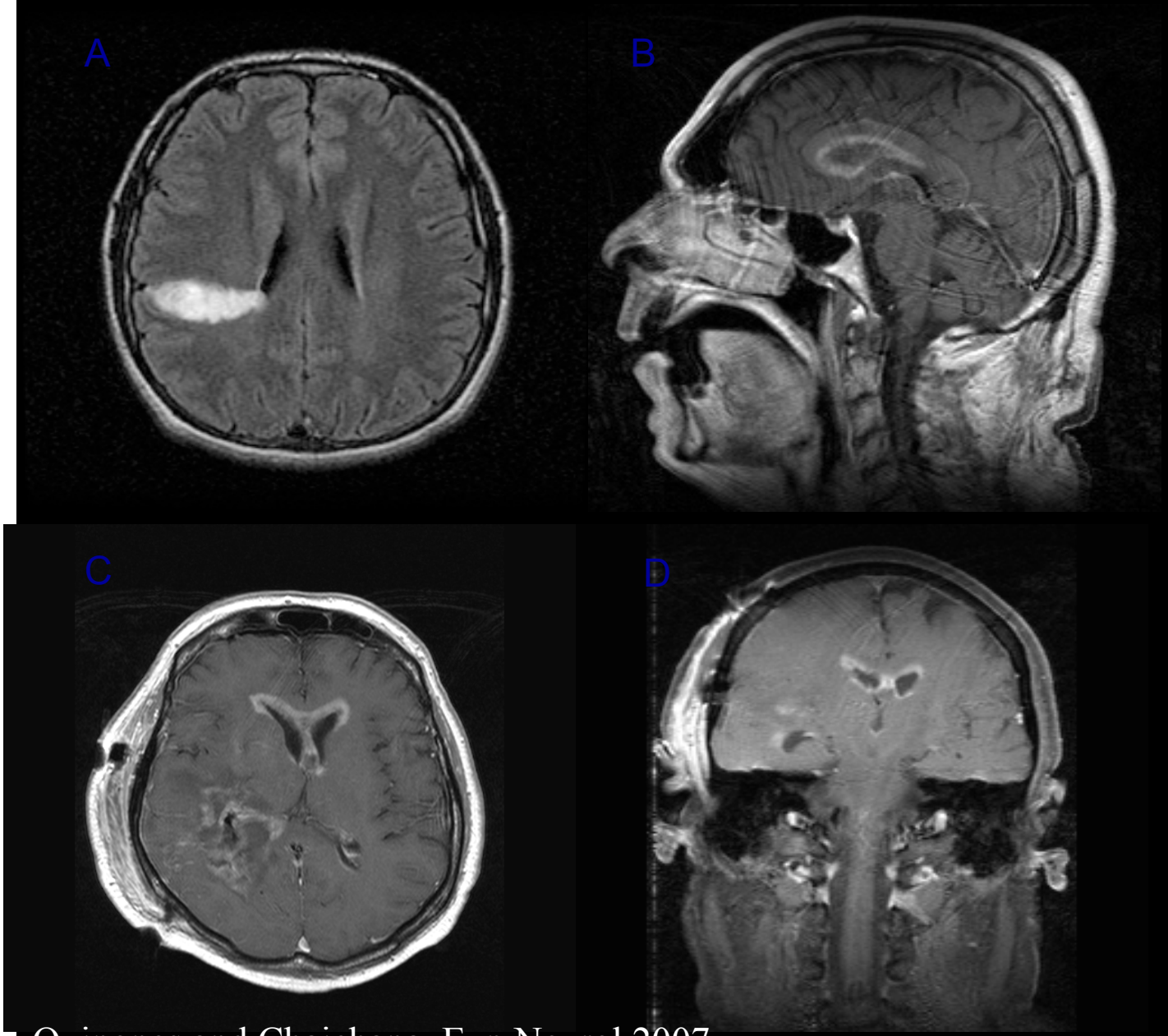

Quinones and Chaichana, Exp Neurol 2007

Matthew J. McGirt, M.D.
Department of Neurosurgery,
The Neuro-Oncology Surgical
Outcomes Research Laboratory,
The Johns Hopkins University
School of Medicine,
Baltimore, Maryland

Debraj Mukherjee, M.D., M.P.H.
Department of Surgery,
The Neuro-Oncology Surgical
Outcomes Research Laboratory,
The Johns Hopkins University
School of Medicine,
Baltimore, Maryland

Kaisorn L. Chaichana, M.D.
Department of Neurosurgery,
The Neuro-Oncology Surgical
Outcomes Research Laboratory,
The Johns Hopkins University
School of Medicine,
Baltimore, Maryland

Khoi D. Than, M.D.
Department of Neurosurgery,
University of Michigan School of Medicine,
Ann Arbor, Michigan

Jon D. Weingart, M.D.
Departments of Neurosurgery
and Oncology,
The Johns Hopkins University
School of Medicine,
Baltimore, Maryland

Alfredo Quinones-Hinojosa, M.D.
Departments of Neurosurgery
and Oncology,
The Neuro-Oncology Surgical
Outcomes Research Laboratory,
The Johns Hopkins University
School of Medicine,
Baltimore, Maryland

Association of Surgically Acquired Motor and Language Deficits on Overall Survival After Resection of Glioblastoma Multiforme

OBJECTIVE: Balancing the benefits of extensive tumor resection with the consequence of potential postoperative deficits remains a challenge in malignant astrocytoma surgery. Although studies have suggested that increasing extent of resection may benefit survival, the effect of new postoperative deficits on survival remains unclear. We set out to determine whether new-onset postoperative motor or speech deficits were associated with survival in our institutional experience with glioblastoma multiforme (GBM).

METHODS: We retrospectively reviewed records of all patients (age range, 18–70 years; Karnofsky Performance Scale score, 80–100) who had undergone GBM resection between 1996 and 2006 at a single institution. Survival was compared between patients who had experienced surgically acquired motor or language deficits versus those who did not experience these deficits.

RESULTS: Three hundred six consecutive patients (age, 54 ± 11 years; median Karnofsky Performance Scale score, 80) underwent primary GBM resection. Nineteen patients (6%) developed surgically acquired motor deficits and 15 (5%) developed surgically acquired language deficits. Median survival was decreased in patients who acquired language deficits (9.6 months; $P < 0.05$) or motor deficits (9.0 months; $P < 0.05$) versus patients without surgically acquired deficits (12.8 months). Two-year survival was 8% and 0% for patients with surgically acquired motor or language deficits, respectively, versus 23% for patients without new-onset deficits.

CONCLUSION: In our experience, the development of new perioperative motor or language deficits was associated with decreased overall survival despite similar extent of resection and adjuvant therapy. Although it is well known that surgically induced neurological deficits affect quality of life, our results suggest that these surgical morbidities may also affect survival. Care should be taken to avoid surgically induced deficits in the management of GBM.

Human Brain

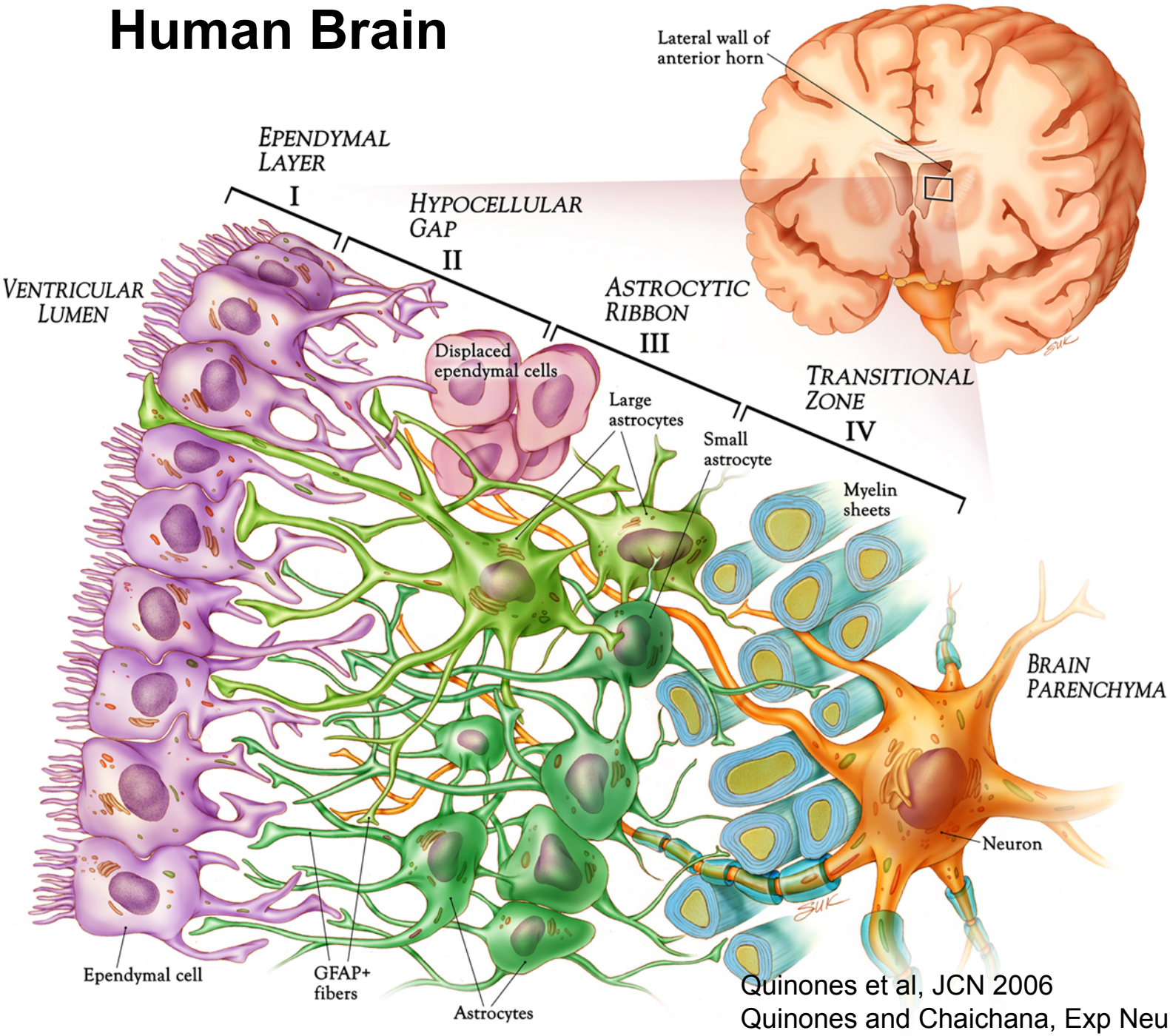

Quinones et al, JCN 2006
Quinones and Chaichana, Exp Neurol 2007

Rodent Brain SVZ

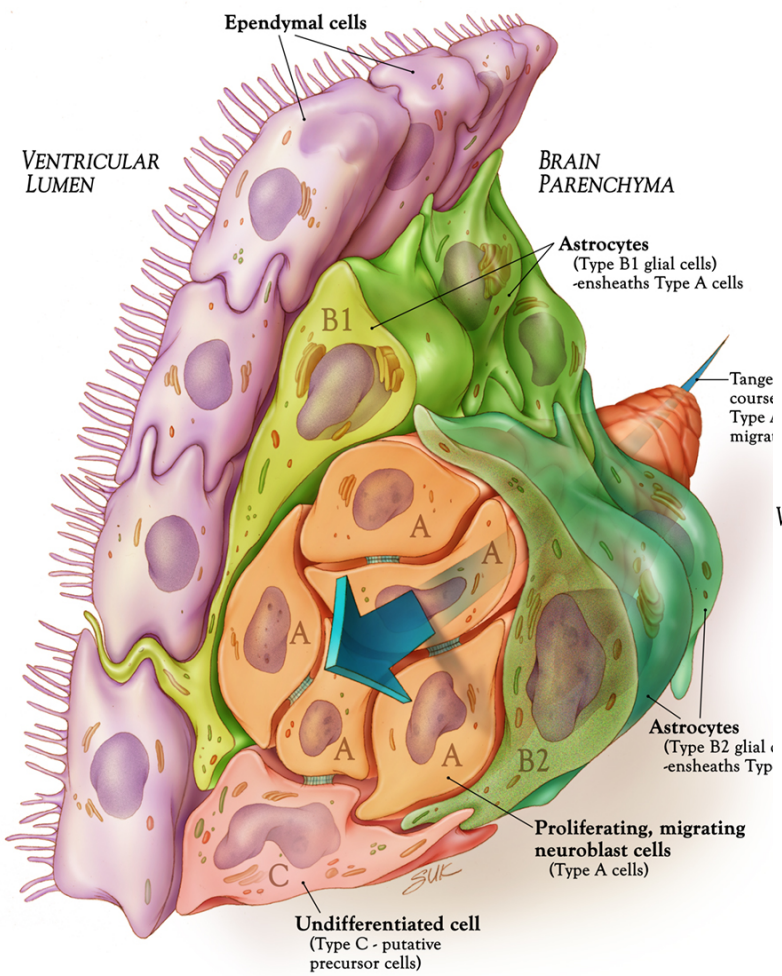

Human Brain SVZ

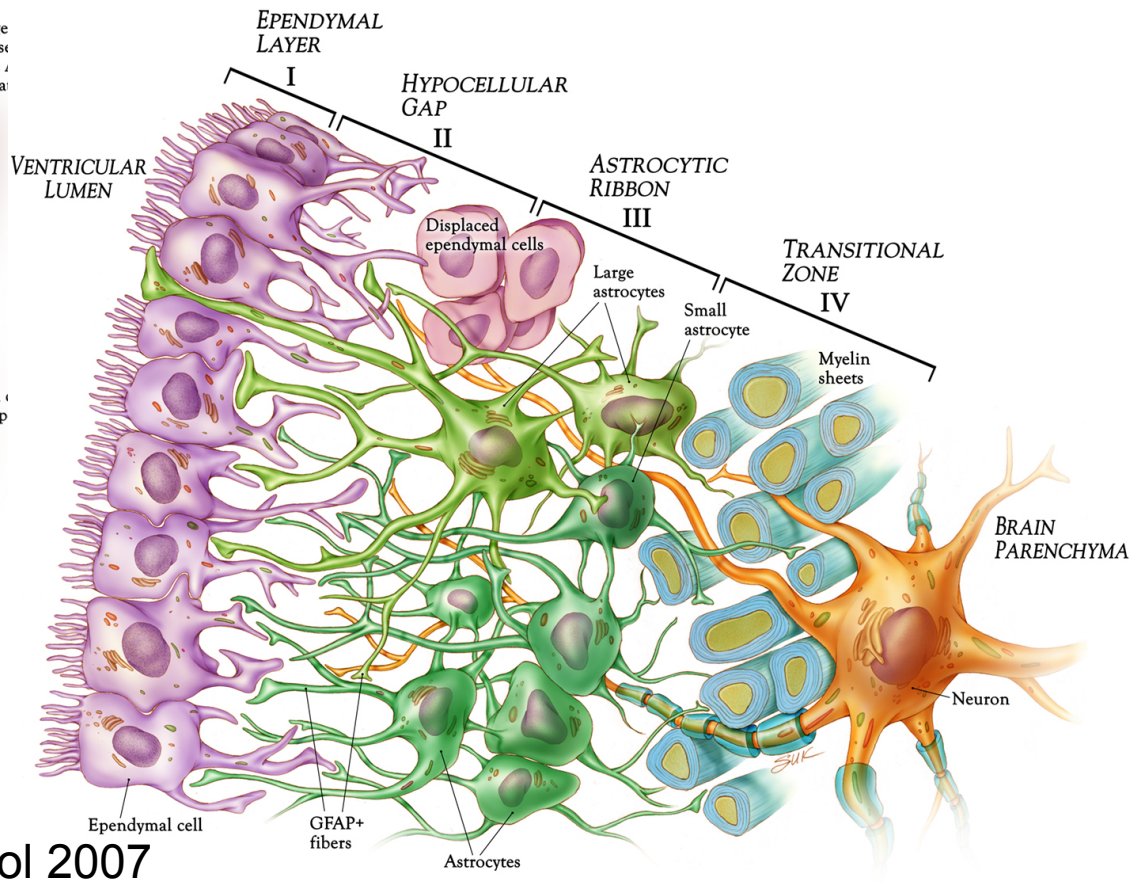

Quinones and Chaichana, Exp Neurol 2007

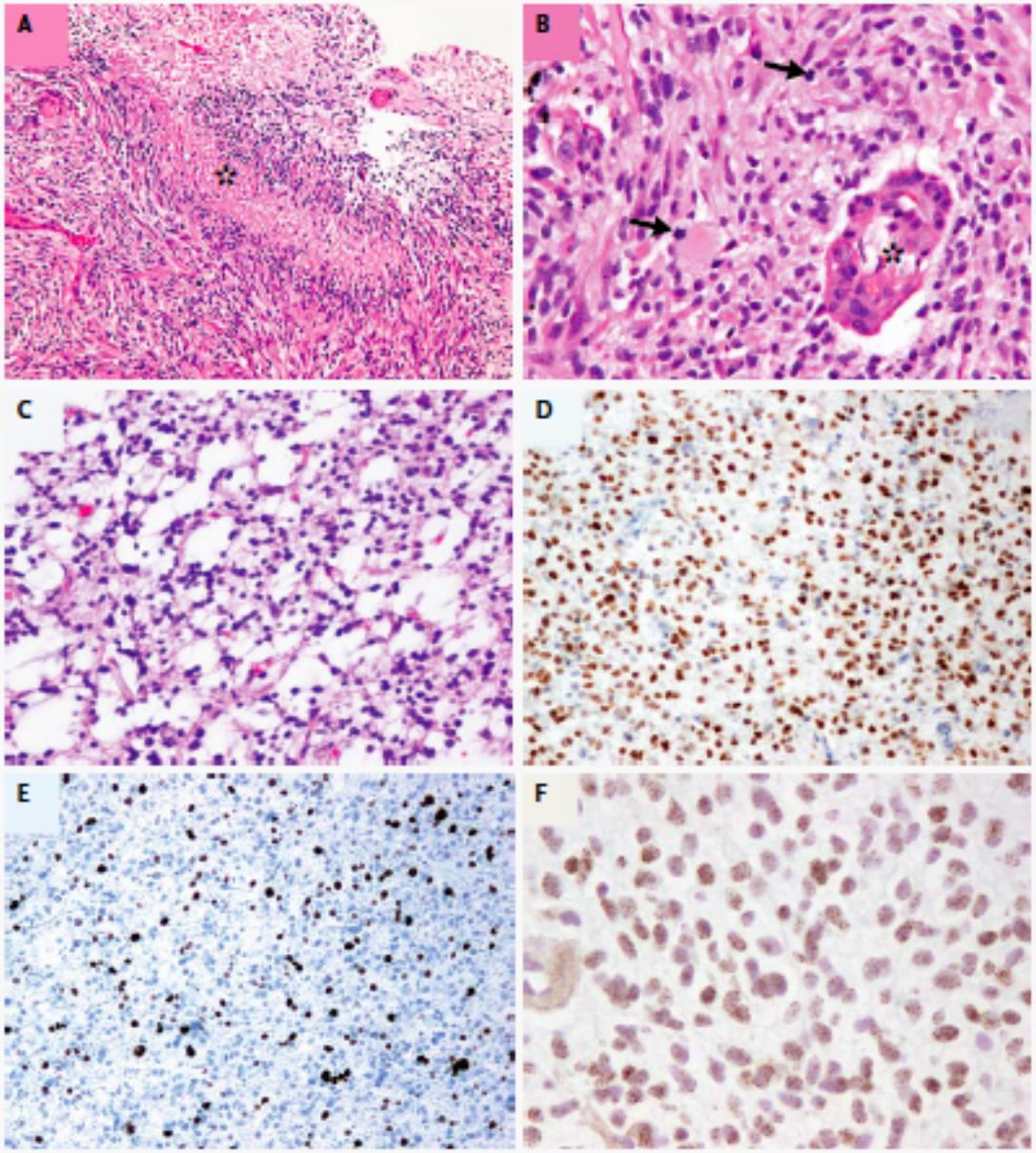

NEJM 2008

Brain Tumors

Alfredo Quiñones-Hinojosa M.D.

Director Brain Tumor Surgery Program
Hopkins Bayview Hospital
Director, Brain Tumor Stem Cell Laboratory
Department of Neurosurgery
The Johns Hopkins University School of Medicine
Department of Oncology, Cellular and Molecular Medicine, Neuroscience
Sidney Kimmel Comprehensive Cancer Center



Intraoperative set up